

Idiopathic focal epilepsies: the “lost tribe”*

Deb K. Pal^{1,2}, Colin Ferrie³, Laura Addis¹, Tomoyuki Akiyama⁴,
Giuseppe Capovilla⁵, Roberto Caraballo⁶,
Anne de Saint-Martin⁷, Natalio Fejerman⁶, Renzo Guerrini⁸,
Khalid Hamandi⁹, Ingo Helbig¹⁰, Andreas A. Ioannides¹¹,
Katsuhiko Kobayashi⁴, Dennis Lal¹², Gaetan Lesca¹³,
Hiltrud Muhle¹⁴, Bernd A. Neubauer¹⁵, Tiziana Pisano⁸,
Gabrielle Rudolf¹⁶, Caroline Seegmuller¹⁷, Takashi Shibata⁴,
Anna Smith¹⁸, Pasquale Striano¹⁹, Lisa J. Strug²⁰,
Pierre Szepietowski²¹, Thalia Valeta²², Harumi Yoshinaga⁴,
Michalis Koutroumanidis²³

¹ Department of Basic & Clinical Neuroscience, Institute of Psychiatry,
Psychology & Neuroscience, King's College London, UK

² Kings College and Evelina Children's Hospitals, London, UK

³ Leeds General Infirmary, Paediatric Neurology, Leeds, UK

⁴ Department of Child Neurology, Okayama University Graduate Schools of Medicine,
Dentistry, and Pharmaceutical Sciences, Okayama, Japan

⁵ Child Neuropsychiatry and Epilepsy Center, C. Poma Hospital, Mantova, Italy

⁶ Neurology Department, Hospital de Pediatría “Prof. Dr. Juan P. Garrahan”,
Buenos Aires, Argentina

⁷ Centre Référent des Epilepsies Rares associé, Centre référent des troubles du langage
et des apprentissages, Hôpitaux Universitaires de Strasbourg, Strasbourg, France

⁸ Pediatric Neurology Unit and Laboratories, Children's Hospital A. Meyer-University
of Florence, Firenze, Italy

⁹ The Alan Richens Welsh Epilepsy Centre, University Hospital of Wales; Cardiff
University Brain Research Imaging Centre, School of Psychology, Cardiff University,
Cardiff, UK

¹⁰ Department of Neuropediatrics, University Medical Center Schleswig-Holstein
(UKSH), Kiel, Germany

¹¹ Laboratory for Human Brain Dynamics, AAI Scientific Cultural Services Ltd., Nicosia,
Cyprus

¹² Cologne Center for Genomics, University of Cologne, Cologne; Department of
Neuropediatrics, University Medical Center Giessen and Marburg Giessen; Cologne
Excellence Cluster on Cellular Stress Responses in Aging-Associated Diseases (CECAD),
University of Cologne, Cologne, Germany

¹³ Department of Genetics, University Hospitals of Lyon; Claude Bernard Lyon I
University; Centre de Recherche en Neurosciences de Lyon, CNRS UMR5292, INSERM
U1028, Lyon, France; French Epilepsy, Language and Development (EPILAND) network

¹⁴ Department of Neuropediatrics, University Medical Center Schleswig-Holstein
(UKSH), Kiel, Germany

¹⁵ Department of Neuropediatrics, University Medical Center Giessen and Marburg,
Giessen, Germany

Correspondence:

Deb K. Pal
Department of Basic & Clinical
Neuroscience, Institute of Psychiatry,
Psychology & Neuroscience,
King's College
London, UK
<deb.pal@kcl.ac.uk>

*This review article is the updated result, edited by M. Koutroumanidis, C. Ferrie and D. Pal, of the Waterloo International Symposium on Idiopathic Focal Epilepsies: Phenotype to Genotype, held at Somerset House, London on 29th September 2012.

¹⁶ Department of Neurology, Strasbourg University Hospital; Strasbourg University; UMR S INSERM U1119, Strasbourg, France; French Epilepsy, Language and Development (EPILAND) network

¹⁷ Centre Référent des Epilepsies Rares associé, Service medico-chirurgical des epilepsies, Hôpitaux Universitaires de Strasbourg, Strasbourg, France

¹⁸ Dept of Basic and Clinical Neuroscience, Institute of Psychiatry, Psychology & Neuroscience, Kings College, London, UK

¹⁹ Pediatric Neurology and Muscular Diseases Unit, Department of Neurosciences, Rehabilitation, Ophthalmology, Genetics, Maternal and Child Health, University of Genova, Institute "G. Gaslini", Genova, Italy

²⁰ Program in Child Health Evaluative Sciences, The Hospital for Sick Children; University of Toronto, Toronto, ON, Canada

²¹ French Epilepsy, Language and Development (EPILAND) network, Aix-Marseille University; INSERM UMR_S901; Mediterranean Institute of Neurobiology (INMED), Marseille, France

²² Department of Clinical neurophysiology, St. Thomas' Hospital, London, UK

²³ GSTT, Clin Neurophysiology and Epilepsies, Lambeth Wing, St Thomas' Hospital, London, UK

Received September 9, 2015; Accepted June 22, 2016

ABSTRACT – The term idiopathic focal epilepsies of childhood (IFE) is not formally recognised by the ILAE in its 2010 revision (Berg *et al.*, 2010), nor are its members and boundaries precisely delineated. The IFEs are amongst the most commonly encountered epilepsy syndromes affecting children. They are fascinating disorders that hold many “treasures” for both clinicians and researchers. For example, the IFEs pose many of the most interesting questions central to epileptology: how are functional brain networks involved in the manifestation of epilepsy? What are the shared mechanisms of comorbidity between epilepsy and neurodevelopmental disorders? How do focal EEG discharges impact cognitive functioning? What explains the age-related expression of these syndromes? Why are EEG discharges and seizures so tightly locked to slow-wave sleep?

In the last few decades, the clinical symptomatology and the respective courses of many IFEs have been described, although they are still not widely appreciated beyond the specialist community. Most neurologists would recognise the core syndromes of IFE to comprise: benign epilepsy of childhood with centro-temporal spikes or Rolandic epilepsy (BECTS/RE); Panayiotopoulos syndrome; and the idiopathic occipital epilepsies (Gastaut and photosensitive types). The Landau-Kleffner syndrome and the related (idiopathic) epilepsy with continuous spikes and waves in sleep (CSWS or ESES) are also often included, both as a consequence of the shared morphology of the interictal discharges and their potential evolution from core syndromes, for example, CSWS from BECTS. Atypical benign focal epilepsy of childhood also has shared electro-clinical features warranting inclusion. In addition, a number of less well-defined syndromes of IFE have been proposed, including benign childhood seizures with affective symptoms, benign childhood epilepsy with parietal spikes, benign childhood seizures with frontal or midline spikes, and benign focal seizures of adolescence.

The term “benign” is often used in connection with the IFEs and is increasingly being challenged. Certainly most of these disorders are not associated with the devastating cognitive and behavioural problems seen with early childhood epileptic encephalopathies, such as West or Dravet syndromes. However, it is clear that specific, and sometimes persistent, neuropsychological deficits in attention, language and literacy accompany many of the IFEs that, when multiplied by the large numbers affected, make up a significant public health problem. Understanding the nature, distribution, evolution, risk and management of these is an important area of current research.

A corollary to such questions regarding comorbidities is the role of focal interictal spikes and their enduring impact on cognitive functioning. What explains the paradox that epilepsies characterised by abundant interictal epileptiform abnormalities are often associated with very few clinical seizures? This is an exciting area in both clinical and experimental arenas and will eventually have important implications for clinical management of the whole child, taking into account not just seizures, but also adaptive functioning and quality of life. For several decades, we have accepted an evidence-free approach to using or not using antiepileptic drugs in IFEs. There is huge international variation and only a handful of studies examining neurocognitive outcomes. Clearly, this is a situation ready for an overhaul in practice.

Fundamental to understanding treatment is knowledge of aetiology. In recent years, there have been several significant discoveries in IFEs from studies of copy number variation, exome sequencing, and linkage that prompt reconsideration of the “unknown cause” classification and strongly suggest a genetic aetiology. The IFE are strongly age-related, both with regards to age of seizure onset and remission. Does this time window solely relate to a similar age-related gene expression, or are there epigenetic factors involved that might also explain low observed twin concordance? The genetic (and epigenetic) models for different IFEs, their comorbidities, and their similarities to other neurodevelopmental disorders deserve investigation in the coming years. In so doing, we will probably learn much about normal brain functioning. This is because these disorders, perhaps more than any other human brain disease, are disorders of functional brain systems (even though these functional networks may not yet be fully defined).

In June 2012, an international group of clinical and basic science researchers met in London under the auspices of the Waterloo Foundation to discuss and debate these issues in relation to IFEs. This Waterloo Foundation Symposium on the Idiopathic Focal Epilepsies: Phenotype to Genotype witnessed presentations that explored the clinical phenomenology, phenotypes and endophenotypes, and genetic approaches to investigation of these disorders. In parallel, the impact of these epilepsies on children and their families was reviewed. The papers in this supplement are based upon these presentations. They represent an updated state-of-the-art thinking on the topics explored.

The symposium led to the formation of international working groups under the umbrella of “Luke’s Idiopathic Focal Epilepsy Project” to investigate various aspects of the idiopathic focal epilepsies including: semiology and classification, genetics, cognition, sleep, high-frequency oscillations, and parental resources (see www.childhood-epilepsy.org). The next sponsored international workshop, in June 2014, was on randomised controlled trials in IFEs and overnight learning outcome measures.

Key words: idiopathic focal epilepsy, Rolandic epilepsy, Panayiotopoulos syndrome, occipital epilepsy (Gastaut type), symptomatic epilepsy, EEG, treatment, prognosis, neuronal circuit, magnetoencephalography, behaviour, language, genetics

Overlap of the core idiopathic focal epilepsies of childhood with other focal symptomatic epilepsies

Renzo Guerrini, Tiziana Pisano

Focal epilepsies have core clinical and EEG characteristics that make early recognition possible in most patients. However, overlap with other focal and possibly symptomatic epilepsy syndromes exists. Some of the features most strongly suggestive of idiopathic focal epilepsy (e.g. normal background EEG activity, EEG discharges with stereotyped waveforms and typical topography, and characteristic clinical manifestations) may also be encountered in symptomatic epilepsies due to structural lesions affecting the Rolandic or occipital cortex. The clinical course of focal idiopathic syndromes may be complicated by cognitive and language impairment. In some cases, the overlap of such core symptoms between idiopathic and symptomatic epilepsy renders the underlying cause a mystery.

Clinical semiologies and electrographic features that highlight the focal origin of seizures characterise the idiopathic focal epilepsies (IFEs) of childhood. They describe a spectrum of syndromes with no underlying structural brain lesion or attendant neurological signs or symptoms. They are presumed to be genetic and are usually age dependent. Their characteristics imply not just the absence of obvious causative factors, but also specific clinical and EEG findings (Berg *et al.*, 2010). The most common forms are benign childhood epilepsy with centro-temporal spikes or Rolandic epilepsy (BECTS/RE) (Beaussart, 1972), early-onset benign childhood occipital epilepsy (Panayiotopoulos type) (Panayiotopoulos, 1989), and late-onset (Gastaut type) childhood occipital epilepsy (Gastaut, 1982). Symptomatic epilepsies, on the other hand, have an acquired or genetic cause and are associated with neuroanatomical or neuropathological abnormalities indicative of an underlying disease or condition. When a genetic mutation causes a brain malformation that results in epilepsy, the epilepsy is considered the result of the interposed brain abnormality, rather than the direct consequence of the genetic abnormality (Berg *et al.*, 2010). In clinical practice, however, distinction between idiopathic and symptomatic focal epilepsies might not always be clear or meaningful, especially when they are associated with specific learning and language problems (Deonna, 1993).

In the IFE, seizures are usually brief, infrequent, and tend to concentrate around preschool or school ages. The EEG background activity and organization of sleep are normal. Focal epileptiform abnormalities have a

characteristic “stereotyped” morphology and are markedly activated by non-REM sleep (Gregory and Wong, 1992). Rolandic epilepsy is the most frequent type of idiopathic focal epilepsy. The age at onset is between 3-13 years. The seizure prognosis is excellent. Seizures are simple partial with motor symptoms involving the face and occur during sleep or on awakening. Often, the seizures show symptoms caused by activation of the Rolandic or perisylvian sensorimotor cortex. Interictal EEG shows typical high-voltage centro-temporal spikes and sharp-waves that increase during sleep. Occasionally, they may occur only in sleep. In most children, drug treatment is not needed (Ambrosetto and Tassinari, 1990).

Some of the same features which, in combination, are strongly suggestive of idiopathic focal epilepsy (e.g. normal EEG background activity, epileptiform discharges with stereotyped wave forms and typical locations, reflex phenomena, and characteristic clinical manifestations) may also be encountered in symptomatic epilepsy due to specific structural lesions affecting the Rolandic or occipital cortex. For example, cortical dysplasia of the Rolandic cortex may cause stereotyped rhythmic sharp-waves with phase reversal over the centro-temporal region and motor seizures affecting one side of the face and the ipsilateral hand, due to the wide area of cortical representation of these body parts. If seizures are not frequent, the EEG background may remain normal. In such circumstances, especially if seizures occur during sleep, early distinction from idiopathic RE may be impossible without an MR scan (*figure 1*). Specific syndromes have been described in which, in addition to the core features of RE, affected patients exhibited clinical features indicating co-occurring dysfunction in wider neuronal networks. For instance, both a familial syndrome of autosomal dominant RE and speech dyspraxia, as well as a recessive syndrome of RE and paroxysmal dyskinesia, have been reported (Scheffer *et al.*, 1995, Guerrini *et al.*, 1999, Kugler *et al.*, 2008). It is unknown whether these conditions represent Rolandic epilepsy “plus” syndromes, which maintain the idiopathic-genetic aetiopathogenic mechanism of RE, or result from “interposed” structural abnormalities affecting the Rolandic cortex as well as additional neural networks.

Some patients with RE show atypical clinical and EEG evolution associated with cognitive dysfunction related to a marked increment of interictal EEG discharges during NREM sleep. This phenomenon has been reported in different syndromes that are thought to belong to the spectrum of RE. Epileptic encephalopathy with continuous spikes and waves during slow-wave sleep (CSWS) is a condition best defined by the associated cognitive or behavioural impairments acquired during childhood and not related to

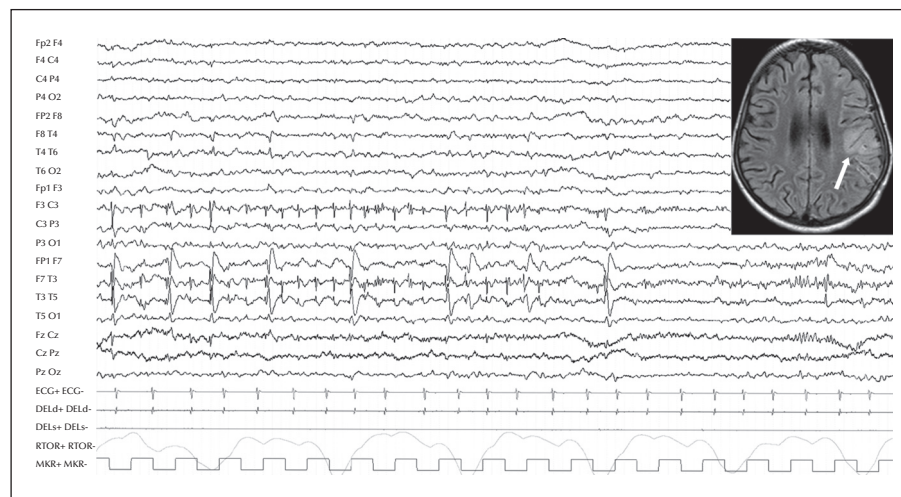


Figure 1. EEG recording of a 4-year-old girl showing normal background activity with superimposed spikes in the left centro-temporal region, and FLAIR MRI showing focal cortical dysplasia involving the left Rolandic region.

any factor other than the presence of frequent interictal epileptiform discharges during sleep. Although this condition is considered by many authors to be part of the childhood focal epilepsy syndromes, it can also be observed in a symptomatic context in children with structural brain lesions, such as polymicrogyria or perinatal ischaemic insults or hydrocephalus (Guerrini *et al.*, 1998; Veggiotti *et al.*, 1999; Guzzetta *et al.*, 2005). Landau-Kleffner syndrome (LKS) is a particular condition in which acquired aphasia is the core manifestation (Cole *et al.*, 1988). Clinical, neurophysiological, and cerebral glucose metabolism data support the hypothesis that interictal epileptiform discharges play a prominent role in the cognitive deficits by interfering with the neuronal networks both at the site of the epileptic foci and at distant, connected areas (Deonna and Roulet-Perez, 2010). Given that CSWS is an age-dependent EEG pattern, the outcome of epilepsy is usually good, irrespective of aetiology, whereas the outcomes of cognition, language, and behaviour are variable.

Childhood occipital epilepsies manifest with a first peak onset at around 2 years old and a second late peak onset between ages 7 to 9 years. In the early-onset form (Panayiotopoulos type), seizures are infrequent and occur at night, usually shortly after the child falls asleep. The episodes typically last a few minutes, but status epilepticus at onset with neurovegetative symptoms may occur (Panayiotopoulos, 1989). A common clinical pattern is one of vomiting and gazing toward one side, often evolving to rhythmic muscle contractions on one or both sides of the body. In the late-onset type (Gastaut type), some children may experience headache and visual symptoms (coloured shapes or flashes of light) associated with the

seizure. The EEG shows sharp waves with maximum occipital negativity, often occurring in long bursts of spike-wave complexes, and markedly activated by eye closure (Gastaut, 1982). Childhood idiopathic occipital epilepsy can be difficult to distinguish from symptomatic causes with less favourable prognoses. The mere presence on EEG of continuous spike-wave activity does not guarantee an "idiopathic" origin, since structural lesions may cause a similar pattern. Perinatal ischaemic insults and cortical malformations are the most frequent causes of occipital epilepsy. Cortical dysplasia, Sturge-Weber syndrome, celiac disease, hyperglycaemia (non-ketotic), Lafora disease, Gaucher disease, and mitochondrial disease can also cause occipital seizures in children (Guerrini *et al.*, 1995).

A syndrome of idiopathic photosensitive occipital lobe epilepsy has been described with onset in adolescence (Guerrini *et al.*, 1995), sometimes overlapping with other types of idiopathic focal epilepsy (Guerrini *et al.*, 1997). In this form, prolonged visual seizures are precipitated by visual stimuli, which seem to act through a mechanism of impaired contrast gain control in the occipital cortex (Porciatti *et al.*, 2000). Notably, similar seizures may also appear in the early phases of some forms of progressive myoclonic epilepsies (Guerrini *et al.*, 2000).

Neuropsychological impairment may occur in children with idiopathic epilepsy syndromes, possibly due to the active phase of epilepsy. The clinical course may be complicated by cognitive and language impairment or behavioural disturbances, with or without CSWS. These functional changes may reflect a particular type of epileptic encephalopathy, in which the epileptiform abnormalities themselves contribute to the progressive disturbance in cerebral function and,

as in symptomatic forms, the patients develop drug-resistant epilepsy and global regression of cognitive function. Some patients, especially those in whom the epileptic process is localised around the perisylvian cortex, present with features of autistic spectrum disorder, but unlike primary autism, there is no loss of social interaction (Deonna and Roulet-Perez, 2010).

Although many clinical, EEG, neuroimaging, and neuropsychiatric features make it possible to differentiate idiopathic from symptomatic focal epilepsy, in some, the number of shared features complicates accurate identification of the underlying cause. In severe phenotypes with RE “plus,” new genetic findings are emerging (Lemke *et al.*, 2013a; Lesca *et al.*, 2013) that might help to fill the gap of knowledge and modifying the concepts on which the dichotomy idiopathic versus symptomatic has traditionally been based.

Atypical clinical presentations of idiopathic focal epilepsies in childhood

Natalio Fejerman, Roberto Caraballo

The concept of “atypical evolution” in idiopathic focal epilepsy refers to both clinical and EEG features that can be seen in several epilepsy syndromes, including atypical benign focal epilepsy of childhood (ABFEC), status of Rolandic epilepsy, Landau-Kleffner syndrome (LKS), and CSWS syndrome. Here, we outline treatment recommendations and discuss prognosis.

Idiopathic focal epilepsies (IFE) appear across a wide range of ages. Due to space limitations, we are going to deal neither with benign familial and non-familial infantile seizures, which are quite frequent, nor with benign focal seizures in adolescents, which are not so frequent, but in our experience are under-diagnosed (Caraballo *et al.*, 2003; Caraballo *et al.*, 2007a). The two main epilepsy syndromes of the IFE appearing in childhood are benign focal epilepsy with centro-temporal spikes or Rolandic epilepsy (RE) and Panayiotopoulos syndrome (PS) (Fejerman, 2008, Panayiotopoulos *et al.*, 2008). Gastaut type of childhood occipital epilepsy is also included in the group of the IFE, but is rare (Caraballo *et al.*, 2008).

Atypical features of RE

Atypical features of RE may be seen in seizure characteristics (daytime-only seizures, post-ictal Todd paresis, prolonged seizures, or even status epilepticus) or on the EEG (atypical spike morphology, unusual location, absence-like spike-wave discharges, or abnormal background) (Aicardi, 2000). Early age at seizure onset

seems to be one of the most important items among the atypical features (Kramer *et al.*, 2002; Saltik *et al.*, 2005; You *et al.*, 2006; Fejerman *et al.*, 2007a). In a retrospective study of 126 patients, atypical features were found in almost half of the patients (Datta and Sinclair, 2007). A follow-up study of RE patients reported a higher percentage of learning and behavioural disabilities in the group with atypical features (Verrotti *et al.*, 2002). In a prospective study of 44 children with RE divided into a typical group ($n=28$) and an atypical group ($n=16$) on the basis of EEGs showing features, such as a slow spike-wave focus, synchronous foci, or generalised 3-Hz spike-wave discharges, the atypical group had significant lower full scale IQ and verbal IQ (Metz-Lutz and Filippini, 2006).

Atypical evolution of RE

The concept of atypical evolutions does not include the cases of RE with atypical features, but refers to the presence of severe neuropsychological impairments that may become persistent. On the EEG, these cases show continuous spikes and waves during slow sleep (CSWSS), which seems to be a kind of bilateral secondary synchrony (Fejerman *et al.*, 2007b). The reasons why some children develop this EEG pattern are still not understood. In some cases, certain anti-epileptic drugs seemed to be responsible (Shields and Saslow, 1983; Caraballo *et al.*, 1989; Prats *et al.*, 1998; Fejerman *et al.*, 2000). These conditions correspond to the syndromes known as atypical benign focal epilepsy of childhood (ABFEC), status of RE (lasting days or weeks) including motor facial seizures and anarthria with persistent drooling (Fejerman and Di Blasi, 1987, Fejerman *et al.*, 2000), Landau-Kleffner syndrome (LKS), and CSWSS syndrome (Tassinari *et al.*, 2005). For example, the cases of ABFEC described by Aicardi and Chevrie (Aicardi and Chevrie, 1982) showed atonic fits leading to daily falls, and all of our cases presented with important learning difficulties during the periods of CSWSS (Fejerman *et al.*, 2007b). Of children with ABFEC, all 11 recovered but five have learning difficulties; language difficulties persisted in two out of three LKS patients; all seven children with status of RE recovered after 3-14 years of follow-up (Fejerman *et al.*, 2000).

In spite of being epileptic encephalopathies within the spectrum of electrical status epilepticus in sleep (ESES) syndromes, ABFEC and status of RE do present a favourable outcome when appropriate therapeutic measures are taken (Fejerman, 1996; Fejerman *et al.*, 2000; Fejerman *et al.*, 2007b). Prognosis of LKS and CSWSS or ESES syndrome instead, is not so good in terms of full recovery.

Nevertheless, in a recent series of 28 symptomatic and 25 idiopathic cases of focal epilepsies associated

with encephalopathy related to ESES receiving add-on therapy with sulthiame, the results were quite encouraging, especially in children with a previous diagnosis of RE or PS (Fejerman *et al.*, 2012). It is interesting to note that a particular group of children with unilateral polymicrogyria may present with the same atypical clinical and EEG evolutions as the patients with IFE responding to therapy in the same way (Caraballo *et al.*, 2007b). Overall, 25 of 33 patients with ABFEC, status of RE, or ESES syndrome eventually became seizure-free.

Are these four conditions (ABFEC, status of RE, LKS and CSWS) independent syndromes or part of a continuum related to RE?

Observations regarding the evolution of clinical and EEG findings identified during the follow-up of patients with RE (above) may not be generalisable to all the cases. Patients with PS and Gastaut type of childhood occipital epilepsy (COE) may show the same atypical electroclinical course (Fejerman *et al.*, 1991). Patients with two types of IFE (*i.e.* RE and PS or RE and Gastaut type of COE) may also develop an atypical evolution (Caraballo *et al.*, 2011c). Another patient studied by our group who had RE and PS and an atypical evolution presented with a mutation in the *GRIN2A* gene (Lemke *et al.*, 2013b).

Is there a relationship between atypical features and what is considered here as atypical evolutions of RE?

It is clear that not all the patients with RE showing atypical clinical and EEG features evolve to ABFEC, status of RE, LKS, or CSWS syndrome. In our series of 39 idiopathic cases of ABFEC, status of RE, LKS and CSWS syndrome appearing after the onset of RE epilepsy started at the age of 4 years or less in 25 patients (Fejerman *et al.*, 2007b). There is no clear explanation for this repeatedly reported observation (Kramer *et al.*, 2002; You *et al.*, 2006). There are also cases of RE who have prolonged intermittent drooling and oromotor dyspraxia associated with a marked increase in centro-temporal spikes during the episodes (Roulet-Perez *et al.*, 1989). Persistent slurred speech as a single phenomenon was also reported (Kramer *et al.*, 2002). Should we consider these cases as having atypical features or do they represent an atypical evolution of RE?

How to prevent the atypical evolutions of IFE of childhood?

Atypical electroclinical features (primarily EEG abnormalities and early age of onset) should be considered as risk factors for atypical evolution (Fejerman *et al.*,

2000; Kramer *et al.*, 2002). Based on an update on the ESES-CSWS syndrome, the subject of therapy was reviewed and it was stated that “an agreement about the optimal treatment of these conditions is still lacking” (Veggiotti *et al.*, 2012). When the mentioned risks are evident, the recommendation is to avoid the classic AEDs (phenobarbital, phenytoin, and carbamazepine) and some of the new AEDs, such as oxcarbazepine, lamotrigine, topiramate, and levetiracetam (Catania *et al.*, 1999; Montenegro and Guerreiro, 2002; Caraballo *et al.*, 2010), and to start treatment with ethosuximide, benzodiazepines, or sulthiame. In refractory cases, corticosteroids may also be considered.

May a genetic aetiology be related to atypical evolutions of IFE?

A genetic aetiology has been proposed in patients with ABFEC and even in patients with epilepsy associated with ESES. This is discussed in detail below (Lesca *et al.*, 2012; Helbig *et al.*, 2014).

In conclusion, a future challenge is to determine if the atypical evolutionary potential within IFEs describes a continuum of expression related to a single genetic aetiology, or if this electroclinical picture is caused by distinct epileptic syndromes. In addition to the importance of the nosological placement, early and correct diagnosis is crucial for optimal therapeutic management and clinical outcomes.

Involvement of autonomic, sensorimotor, auditory, vocal, and visual circuits in idiopathic focal epilepsies

Giuseppe Capovilla and Pasquale Striano

Idiopathic focal epilepsies (IFE) affect over 20% of children with non-febrile seizures and constitute a significant part of the everyday practice of epileptologists. They have distinctive characteristics but they also share common clinical and EEG features and it has been suggested that they may be linked together in a broad, age-related and age-limited, genetically determined, *benign childhood seizure susceptibility syndrome*. Although rare, IFEs may be complicated by a broad range of cognitive problems, behavioural disturbances, and resistance to medical therapy that can impact brain maturation and the development of cognitive skills. Recent opinions suggest that IFEs are caused by perturbations of localised processes involving different brain areas, which in some cases can evolve to a global network disturbance.

While IFEs affect over 20% of children with non-febrile seizures, the category is not specifically recognised

by the ILAE. This chapter focuses on three electroclinical syndromes, subtypes of IFE, recognised by the International League against Epilepsy (ILAE) (Engel, 2006): Panayiotopoulos syndrome, Rolandic epilepsy, and occipital epilepsy of Gastaut type. Other putative forms include: focal epilepsy with parietal spikes/giant somatosensory evoked spikes (de Marco and Tassinari, 1981) and focal epilepsy with frontal or midline spikes during sleep (Beaumanoir and Nahory, 1983; Capovilla *et al.*, 2006). Each form has distinctive characteristics but they also share common clinical and EEG features. Seizures are infrequent, usually nocturnal and remit within a few years from onset. Brief or prolonged seizures, even focal status epilepticus, may occur only once in the patient's lifetime. Neurological and cognitive function, as well as brain imaging, are normal in patients with IFE. It has been suggested that all of these conditions may be linked together in a broad, genetically determined, age-related and age-limited benign childhood seizure susceptibility syndrome (Panayiotopoulos, 1993; Panayiotopoulos *et al.*, 2008; Gaggero *et al.*, 2014). Rarely, IFEs may be complicated by pharmacoresistance, behavioural disturbances, or a range of cognitive impairments, particularly troublesome in childhood given the brain's developmentally vulnerable state, a time during which neurological disturbances can profoundly impact brain maturation and the development of cognitive skills (Braakman *et al.*, 2011).

Involvement of autonomic circuits in IFE:

Panayiotopoulos syndrome

Panayiotopoulos syndrome (PS) is a common idiopathic childhood-specific epilepsy. It is characterised by seizures, often prolonged, with predominantly autonomic symptoms and shifting and/or multiple foci, often with occipital predominance on EEG (Panayiotopoulos, 1993; Panayiotopoulos, 2007; Panayiotopoulos *et al.*, 2008; Capovilla *et al.*, 2009). Onset is from age 2 to 11 years with 76% starting between 3 and 6 years. The hallmark of PS is ictal autonomic alterations that may involve any function of the autonomic system and mainly emesis. Other autonomic manifestations include pallor, sphincteric incontinence, hypersalivation, cyanosis, mydriasis or miosis, coughing, abnormalities of intestinal motility, breathing, cardiac irregularities, and syncopal-like manifestations (Koutroumanidis, 2007). Pure autonomic seizures or status epilepticus appear to occur in 10% of patients. However, autonomic manifestations are usually followed by conventional seizure symptoms. Converging evidence from multiple and independent clinical, EEG, and magnetoencephalographic studies has documented Panayiotopoulos

syndrome as a model of childhood autonomic epilepsy (Panayiotopoulos *et al.*, 2008).

Autonomic symptoms are usually generated by activation or inhibition of parts of the central autonomic network that involves the insular cortex, medial prefrontal cortex, amygdala, hypothalamus, and ventrolateral medulla (Goodman *et al.*, 2008). In PS, the neuroanatomical and neurophysiological underpinnings of autonomic manifestations are unknown, but it has been suggested that the preferential involvement of emetic and other autonomic manifestations in PS may be attributed to a maturation-related susceptibility of the central autonomic network (Panayiotopoulos *et al.*, 2008) which has a lower threshold to epileptogenic activation than those producing focal cortical semiology. Thus, irrespective of the localisation of their onset, ictal discharges may activate the lower threshold autonomic centres (and therefore produce autonomic manifestations) commonly before other cortical regions of relatively higher threshold that generate focal cortical symptoms (sensory, motor, visual or other). Seizures remain purely autonomic if ictal neuronal activation of non-autonomic cortical areas fails to reach symptomatogenic threshold; otherwise, they consist of autonomic and localisation-related cortical symptoms and signs that may only rarely occur from onset. This hypothesis may explain why similar autonomic manifestations may appear from anterior or posterior, or right or left brain onsets. In this sense, as seizures primarily involve a particular system (the autonomic), PS may be considered as an electroclinical example of "system epilepsy" (see below).

Involvement of sensorimotor and auditory vocal circuits in IFE: ***Rolandic epilepsy***

Rolandic epilepsy (RE) or benign childhood epilepsy with centro-temporal spikes is the most common childhood focal epilepsy (Fejerman, 2008; Panayiotopoulos *et al.*, 2008), usually starting between 7 and 10 years. The cardinal features are focal seizures consisting of unilateral facial sensory-motor symptoms, oropharyngo-laryngeal symptoms, speech arrest, and hypersalivation (Capovilla *et al.*, 2011). Centro-temporal spikes, typically activated by drowsiness and slow sleep, indicate that the epileptogenic zone in Rolandic epilepsy involves neuronal networks within the Rolandic cortex surrounding the central fissure bilaterally. Indeed, RE reflects an age-related maturational instability of the lower Rolandic (somatosensory) cortex that represents the face and the oropharynx bilaterally (Panayiotopoulos *et al.*, 2008). Over the last years, evidence has accumulated that even RE is associated with language impairment, although the cerebral mechanism through which

epileptiform activity in the Rolandic areas may affect the language system is still unclear. Functional magnetic resonance imaging (fMRI) data support a functional deficit of the default mode network (DMN). This dysfunction is most apparent in the precuneus, a key region of the DMN. In particular, children with RE show reduced activation of the DMN during the rest condition and a deactivation during cognitive effort (Besseling *et al.*, 2013a). In addition, reduced functional connectivity was demonstrated between the sensorimotor network and the left inferior frontal gyrus (Broca's area), which might link seizure activity, originating from the sensorimotor cortex to language impairment (Oser *et al.*, 2014).

It is also well known that RE may rarely evolve to more severe syndromes with behavioural and neuropsychological deficits, such as epilepsy with continuous spike-and-wave during sleep (CSWS) (Patry *et al.*, 1971; Striano and Capovilla, 2013) and the broad spectrum of age-related epileptic conditions characterised by the EEG pattern of electrical status epilepticus during sleep, including atypical epilepsy with centro-temporal spikes and Landau-Kleffner syndrome. The pathophysiological mechanisms underlying this cognitive derailment are also incompletely understood. The abnormal EEG activity is probably due to the activation of the reticulo-thalamic-cortical system with secondary bilateral synchronization through the corpus callosum, as supported by the activation of epileptiform activity during sleep (Striano and Capovilla, 2013). As the duration of CSWS and the localisation of interictal foci influence the degree and type of cognitive dysfunction, it is likely that the epileptic activity occurring during sleep causes the typical clinical symptoms by interfering with sleep-related physiological functions, and possibly neuroplasticity processes mediating higher cortical functions, such as learning and memory consolidation (Striano and Capovilla, 2013). fMRI studies also suggest that the neurophysiological effects of CSWS activity are not restricted to the epileptic focus but spread to connected brain areas via a possible mechanism of surrounding and remote inhibition, possibly having long-lasting consequences on normal brain function, organization, and maturation (Van Bogaert, 2013). Moreover, in patients with CSWS, EEG-fMRI results during drug-induced sleep show a complex pattern of activation involving the perisylvian/prefrontal cortex, the thalamus, and a deactivation of DMN (Siniatchkin *et al.*, 2010). A dysfunction of these networks is a possible explanation for the observed neuropsychological disorders.

Landau-Kleffner syndrome (LKS), also known as acquired epileptic aphasia, is an acquired childhood disorder consisting of auditory agnosia, associated with focal or multifocal spikes or spike-and-wave discharges, nearly continuous during sleep (Landau

and Kleffner, 1957). Although LKS patients often appear to be deaf, their normal audiograms and auditory evoked potentials support the concept that there is an underlying disorder of cortical processing of auditory information, a "verbal-auditory agnosia" (Landau and Kleffner, 1957). The aphasia in these children may be only one component of a more complex neuropsychological disorder associated with other cognitive and behavioural deficits. EEG-fMRI studies suggest that pathophysiological effects associated with CSWS activity are not restricted to the epileptic focus, but spread to connected areas due to remote functional consequences, such that the spike-associated deactivation of DMN is a further consequence of the individual focus of epileptic activity. This phenomenon has been defined as the "network inhibition hypothesis", by which increased cortical activity in one region inhibits subcortical arousal systems, leading to widespread decreased cortical activity, including the DMN (De Tiege *et al.*, 2008).

Involvement of visual circuits in IFE: *occipital epilepsy of Gastaut*

Occipital epilepsy of Gastaut is a rare form of pure occipital epilepsy accounting for about 2-7% of benign childhood focal seizures (Gastaut, 1982; Panayiotopoulos *et al.*, 2008). The age at onset ranges from 3 to 15 years with a peak between 8 and 11 years. Elementary visual hallucinations are frequently the first and often the only seizure symptom. Complex visual hallucinations such as faces and figures, and visual illusions such as micropsia, palinopsia and metamorphopsia occur in <10% of patients and mainly after the appearance of elementary visual hallucinations (Gastaut, 1982; Panayiotopoulos *et al.*, 2008). The epileptogenic zone involves networks within the occipital lobes and this localisation is congruent with the symptomatogenic zone. Little is known about the cortical areas involved in spike or seizure generation in this syndrome, but recent fMRI studies suggest that the epileptogenic area is localised in the medial parietal areas of both hemispheres (Leal *et al.*, 2006).

Discussion

Based on the current knowledge, it is reasonable to state that IFEs are likely to be linked together by a genetically determined, functional derangement of brain maturation that is mild and age related (Panayiotopoulos *et al.*, 2008). In fact, despite the distinctiveness of their core clinical and EEG features, these syndromes may show significant reciprocity. Children with RE may present with autonomic seizures referable to PS, while others may alternately

have autonomic and Rolandic seizures. A small number of susceptible children may also have minor and fully reversible neuropsychological symptoms that are rarely clinically overt and can be detected only by formal neuropsychological testing. However, in a very limited number of patients, the disturbance of brain maturation may further evolve into a more aggressive clinical state with enduring neuropsychological consequences. Clearly, the spectrum of neuropsychological disorders depends not only on the location of the epileptic focus and its duration, but also on the connected cortical and subcortical areas, where specific patterns of spike-induced activation (especially in perisylvian and/or prefrontal areas) and DMN deactivation underlie the dysfunction of neuropsychological circuitry. Each function and its correspondent system needs to be studied with a dynamic approach that pinpoints how one part of the developing system might interact differently with other parts and at varying epochs across ontogenesis. Functional connectivity can be measured by correlating blood-oxygen-dependent oxygenation (BOLD) related dynamic fluctuations of grey matter activity between different brain regions, however, additional prospective studies using functional neuroimaging are needed to better understand the interaction between DMN deactivation and the other systems and its developmental milestones (Filippini *et al.*, 2013).

In the last few years, some authors postulated the concept of “system epilepsies”. Data supporting this hypothesis, that some types of epilepsy depend on the dysfunction of specific neural systems, are reviewed elsewhere (Wolf, 2006; Capovilla *et al.*, 2009; Avanzini *et al.*, 2012). Briefly, the “system epilepsy” hypothesis implies that some types of epilepsy reflect the pathological expression of an identifiable neural system, made up of brain areas, which subserve normal physiological functions and that constitute a pre-existing functional system (as in RE and related syndromes with the involvement of the sensory-motor system), or with the birth of pathological systems as in West and Lennox-Gastaut syndrome. According to the “system epilepsy” hypothesis, dysfunction of a single brain structure cannot be solely responsible for the complex manifestations of these epileptic syndromes. Instead, their full electroclinical picture requires a pathological system in which different brain areas (the cortex, thalamic nuclei, and brainstem) work together, actively and simultaneously participating in the epileptogenic process. When some of these stations are not involved in the pathological epileptic process, other and less complex electroclinical phenotypes develop. fMRI studies (Capovilla *et al.*, 2013; Siniatchkin and Capovilla, 2013) can help to document the active and simultaneous participation of these different brain areas and thus allow us to better understand the

neuropathophysiological process. An enriched awareness of the basis for cognitive impairment in children with epileptic encephalopathies may help with the design of more effective and targeted therapeutic strategies. As epileptic encephalopathies can complicate IFEs, it is vital that the identification and treatment of developmental, behavioural and psychiatric comorbidities are not neglected and that a rational, holistic approach is taken to the management of epileptic syndromes in infancy and childhood.

How useful are individual interictal EEG abnormalities in diagnosing the specific syndrome of idiopathic focal epilepsy?

Harumi Yoshinaga, Katsuhiro Kobayashi,
Tomoyuki Akiyama, Takashi Shibata

We consider how useful individual EEG abnormalities are in the diagnosis of the main syndromes within the spectrum of idiopathic focal epilepsy (IFE), especially Panayiotopoulos syndrome (PS), and in further understanding of the underlying pathophysiology. PS has high dipole stability, similar to that of benign epilepsy in childhood with centro-temporal spikes (BECTS). Preceding positive spikes (PPSs) accompany not only the Rolandic spikes in BECTS, but are also detected with the Rolandic spikes observed in PS. However, they are rarely observed with spikes from patients with febrile seizures (FS). These electroencephalographic findings indicate a close link between these two syndromes. We believe that a source(s) of the PPSs and a separate source of the main Rolandic spike, each representing two proximal populations of neurons in the inferior part of the Rolandic cortex, are necessary for the development of the Rolandic seizures that are characteristic of BECTS, but may also occur in PS. Epileptic high-frequency oscillations (HFOs) may be related to the neuropsychological regression that accompanies the extraordinary EEG abnormalities of epilepsy with continuous spike-waves during slow-wave sleep (CSWS). They also appear to correlate with the severity of IFE (Kobayashi *et al.*, 2010; Kobayashi *et al.*, 2011). In conclusion, conventional EEGs and advanced EEG analysis techniques are both useful tools for diagnosing IFE and for investigating the pathophysiology of IFE-spectrum syndromes. Benign childhood epilepsy with centro-temporal spikes (BECTS) and the occipital lobe epilepsy of Gastaut type are representative IFEs. Both have straightforward electroclinical phenotypes with Rolandic spikes and Rolandic seizures in the former and occipital spikes and visual seizures in the latter. On the other hand, Panayiotopoulos syndrome, the youngest

member of IFE, manifests with occipital and extra occipital spikes. Its characteristic seizures include mainly autonomic symptoms, which are not referable to distinct cortical areas. Conventional EEG cannot fully clarify the electroclinical correlations in PS nor confirm the EEG characteristics of PS as a distinctive type of IFE. In this report, we evaluate the EEG findings of PS with various modern techniques including dipole analysis, sequential mapping, and HFO analysis, to better delineate both its features as an IFE and the mechanisms that underlie seizure manifestations.

What are the common EEG features of idiopathic focal epilepsy (IFE)?

Dipole characteristics

Several dipole analysis studies of benign childhood epilepsy with centro-temporal spikes (BECTS) have unanimously documented good dipole stability (Wong, 1989; Yoshinaga *et al.*, 1992). Wong (1989) reported greater dipole stability in typical BECTS compared to atypical BECTS with intellectual disability. He hypothesized that even if a common generator were present in the atypical group, as is the case in typical BECTS, the former would contain additional extraneous interactions and would not show a stable dipole.

PS is a benign idiopathic epilepsy of early childhood similar to BECTS of late childhood (Panayiotopoulos *et al.*, 2008). Several reports have suggested that the two conditions may be linked (Yoshinaga *et al.*, 2005; Yoshinaga *et al.*, 2006; Koutroumanidis, 2007; Panayiotopoulos *et al.*, 2008). We have previously published a report on dipole analysis in PS and showed intra- and inter-individual dipole stability similar to BECTS using single spike analysis (Yoshinaga *et al.*, 2005). Moreover, we carried out advanced dipole analysis using spike selection that was performed objectively using a computer detection program followed by automatic clustering analyses (Yoshinaga *et al.*, 2006). This program identifies clusters of spikes based on similar morphology and topography. We compared the dipoles of occipital spikes observed in the PS (Group A) to those observed in other groups (Group B). We analysed the dipoles of the averaged spike in each patient. In Group A, the averaged occipital spikes in each patient showed dense dipole locations in the mesial occipital area, while in Group B, dipole locations were widely scattered. In Group A, the geometric centres of the dipoles at each time point (such as at the main negative peak and the preceding or following positive peak) were estimated in the neighbouring locations. In contrast, they tended to be scattered in Group B. Our study revealed that PS has high dipole stability, similar to that of BECTS. From the electroencephalographic point of view, this could indicate a close link between these two syndromes.

Preceding positive spikes

van der Meij and colleagues (van der Meij *et al.*, 1992) focused primarily on the preceding positive spikes (PPSs) observed in Rolandic spikes, and concluded that the occurrence of a PPS before the prominent Rolandic spike is significantly related to Rolandic seizures (Loiseau and Beaussart, 1973). Their hypothesis is that PPSs originate from a specifically oriented population of neurons located in a gyrus of the inferior part of the Rolandic cortex (van der Meij *et al.*, 1993).

To clarify the clinical implications of the PPSs within IFE, we analysed PPSs in the Rolandic and occipital spikes in children with two types of IFE (BECTS and PS), as well as in children with febrile seizures (FS) (Yoshinaga *et al.*, 2013). We generated an averaged spike for each patient from the Rolandic and occipital spikes that were detected using an automatic spike detection and clustering system. We compared the PPS ratio among the three groups (BECT vs. PS vs. FS) using sequential mapping. We included 25 children with BECTS, 18 with PS, and 15 with FS and Rolandic spikes. PPS in the averaged Rolandic spikes occurred in 15 children with BECTS and nine with PS, but only in four with FS. Three of these four children with FS later developed afebrile seizures, and one of them was diagnosed with PS. We then analysed eight PS and six FS children with occipital spikes: PPS occurred in five children with PS but only in one with FS. This FS patient later developed prolonged autonomic febrile seizures. In conclusion, PPSs are not specific to Rolandic spikes in BECTS, but are also detected in Rolandic and occipital spikes observed in PS, while they are rare in FS. These findings suggest a strong correlation of PPSs with epileptogenesis.

What causes the differences in the clinical features between patients with benign epilepsy with centro-temporal spikes and those with Panayiotopoulos syndrome?

The characteristic seizure manifestations of BECTS indicate a sensory motor cortex origin (Loiseau and Beaussart, 1973). In contrast, the seizure semiology of PS is characterised mainly by autonomic symptoms, particularly vomiting, which indicate no specific cortical area as the site of seizure onset (Koutroumanidis, 2007; Panayiotopoulos *et al.*, 2008). Centro-temporal spikes (also known as Rolandic spikes) are the hallmark of BECTS, whereas the interictal EEGs in PS show greater variability in spike topography, with a predominance of occipital spikes and an appreciable number of Rolandic and other multifocal spikes (Covanis *et al.*, 2003; Specchio *et al.*, 2010).

Van der Meij and colleagues (van der Meij *et al.*, 1993) reported that the source of PPSs was the inferior part of

the Rolandic cortex, which is located near the source of the main Rolandic spikes. They hypothesized that the presence of the main Rolandic spikes alone was insufficient to account for the clinical symptomatology of Rolandic seizures and that the existence of the PPS-generating site was necessary for the development of seizures.

However, as mentioned, our study indicated that PPS are not specific to Rolandic spikes in BECTS, but are also detected in Rolandic spikes observed in PS, and rarely in those in FS (Yoshinaga *et al.*, 2013). These findings do not support van der Meij and colleagues' hypothesis (van der Meij *et al.*, 1993). Such conflicting evidence motivated us to study the characteristics of Rolandic spikes in the two syndromes.

Ictal EEGs

Nearly 10% of children with PS develop pure Rolandic seizures at the same or at a later age (Caraballo *et al.*, 2007). BECTS and PS have different pathophysiologies and seizure types, but share some clinical and EEG features. To further investigate these relationships, we studied five children who had experienced both characteristic types of seizure manifestations, namely Rolandic and emetic seizures (Yoshinaga *et al.*, 2015). We found that they all showed Rolandic spikes when they had Rolandic seizures and occipital or multifocal spikes when they had emetic seizures. We also reported in detail a girl who showed two different types of ictal EEG pattern: one starting in the occipital area with associated prolonged emetic symptoms and one starting from the Rolandic area, associated with facial twitching. We have also seen a boy with PS and interictal Rolandic spikes who showed focal slowing over the occipital area and posterior spikes one day after an emetic seizure. Based on this evidence, we believe that the participation of the occipital area is important in PS, even when the patient shows Rolandic spikes on their EEG.

Dipole location of Rolandic spikes

We have performed a preliminary study in which we compared the dipole location of Rolandic spikes observed in 21 children with BECTS (Group A) and 10 children with PS (Group B). We analysed both the onset dipoles for PPS and the peak dipoles for the main spikes of the averaged Rolandic spike in each patient and found that onset dipoles in both groups were widely distributed in the Rolandic area without any particular differences. In contrast, there was a significant difference in peak dipole locations between the two groups, especially in the Y and Z axes. Dipoles in the BECTS group were located lower and were more tightly clustered than those in the PS group. Thus, peak

dipoles in BECTS corresponded well to the ictal symptom of facial twitching. However, peak dipole locations in PS were more widely distributed in the Rolandic area, where an actual epileptogenic focus may not exist. Moreover, the migration distance between the main dipoles and the onset dipoles was different between the two syndromes. The main dipoles and the onset dipoles were more closely located in BECT than in PS, especially in the Z axis direction.

To summarise, it appears that the source of the PPS and the source of the main Rolandic spike represent two proximal populations of neurons in the inferior part of the Rolandic cortex and are necessary for the development of the characteristic Rolandic seizures, as proposed by van der Meij *et al.* (1993).

What determines the individual severity of epilepsy in IFE?

There is a spectrum of paediatric epileptic disorders extending from the benign end of BECTS to the encephalopathic end of epilepsy with CSWS (Tassinari *et al.*, 2000), raising the question of what determines the individual severity of epilepsy in IFE.

We have been trying to detect gamma and high-frequency oscillations (HFO) on scalp EEGs in childhood epilepsies. Because HFOs may affect normal brain functions, we examined them in 10 children with CSWS (Kobayashi *et al.*, 2010), aged six to nine years. We were able to detect HFOs in the time-expanded EEG tracings during slow-wave sleep, but not after CSWS subsided, leaving random focal spikes on the EEG. During CSWS, the frequency of the high-frequency peak with the greatest power in each patient's spectra ranged from 97.7 to 140.6 Hz.

In another study of children with BECTS (Kobayashi *et al.*, 2011), we found that the frequency of HFOs was similar to that in CSWS, but their magnitude was much smaller. Therefore, HFOs of high magnitude are related to CSWS and their presence may indicate a poor prognosis. We have also found that HFOs are observed during the period of active seizure occurrence. Interictal spikes tend to persist after seizure cessation, but HFOs disappear and their presence may therefore reflect epileptogenicity (Kobayashi *et al.*, 2011).

Physiological high-frequency activity is believed to play an important role in higher brain functions, including memory, language, and cognition (Kobayashi *et al.*, 2010). We hypothesize that it is unlikely that physiological and pathological HFOs coexist in the same brain without interaction and that epileptic HFOs may relate to the neuropsychological regression that accompanies the extraordinary EEG abnormalities of CSWS. Epileptic HFO also appear to correlate with the severity of IFE.

Conclusion

Conventional EEGs and advanced EEG analysis techniques are both useful tools for diagnosing IFE and for investigating the pathophysiology of IFE-spectrum syndromes. Further investigations are needed to elucidate the mechanisms underlying the unique clinical seizure manifestations observed in Panayiotopoulos syndrome.

Magnetoencephalography in the idiopathic focal epilepsies of childhood

Khalid Hamandi, Andreas A. Ioannides

Magnetoencephalography is an established and now, in light of hardware and software computational advances, rapidly developing technology. The idiopathic focal epilepsies (IFE) typically show unilateral, and occasionally bilateral or multi-focal interictal epileptic discharges on EEG. These readily lend themselves to more detailed neurophysiological study with magnetoencephalography. This review focuses on the existing magnetoencephalography literature in the IFEs. Studies show that stable dipolar sources of interictal epileptiform discharges that characterise the IFEs are, in some studies, associated with more detailed phenotypic characteristics. Recently, sample sizes have increased and attention is moving to novel analysis strategies and time-frequency analysis approaches. The ultimate objective of these studies is a greater understanding of the generators of epileptic activity and their relationship to clinical and neuropsychological phenotypes.

Focal interictal epileptiform discharges (IEDs) define the IFEs (Legarda *et al.*, 1994). This defining neurophysiology motivates studies using magnetoencephalography (MEG) in understanding seizure phenomenology, exploring aetiology and identifying clinical biomarkers. This article provides an initial overview of magnetoencephalography, a review of published MEG studies on IFE, and a discussion of recent MEG methodological developments and potential future contributions.

Magnetoencephalography

Background

MEG detects the minute changes in the magnetic field just outside the head that are generated by coherent electrical currents within the brain. EEG detects the changes in electrical potential between scalp electrodes generated by the same electrical currents in the brain that generate the MEG field. Until the 1990s, only a single sensor, or arrays with few sensors covering

only part of the head, were available. This understandably limited the utility of MEG as a diagnostic tool. Modern MEG scanners have 300 to 400 channels, arranged in a helmet-like liquid helium dewar, allowing simultaneous whole-head recordings.

Source localisation

A number of methods are available to model the generators of EEG and MEG. The single and multiple equivalent current dipole (ECD) are models that approximate the electrical current generators to one or more point source(s). The single ECD model has been most commonly used in localising putative epileptic spike sources in epilepsy. A different method of source localisation uses beamformer techniques. Here, the pattern of sensitivity of each sensor and the statistical properties of the signal are used to produce a spatial filter that extracts an estimate of the signal from given points in the brain based on the signal of all sensors. A number of beamformer methods exist, the commonest used in MEG is Synthetic Aperture Magnetometry or SAM (Vrba and Robinson, 2001). SAM can be used to extract the source time course from one or more specified locations. A further adaption of the SAM, known as SAMg2, identifies excess kurtosis that can be generated by the sharp waveform of epileptic spikes (Robinson *et al.*, 2004).

SAM is part of a wide range of methods that rely on the linearity of the forward problem to reduce source analysis to a matrix inversion operation (e.g. using the spatial filter in the case of SAM) (*figure 2*). For different reasons, the ECD and linear methods can work well when one, or few focal generators dominate the signal, or some property of the source (sparse nature, distinct oscillatory or spiky pattern) can provide an additional handle that can be incorporated as a constraint within the linear framework. In other cases, the source reconstruction problem requires a non-linear approach with magnetic field tomography (MFT), with optimal properties for tomographic analysis (Taylor *et al.*, 1999). A non-linear approach to the inverse problem is computationally intensive and has so far not been widely applied to epilepsy.

Magnetoencephalography and IFE

Studies have focused on spike localisation, their relationship to clinical features, and more recently time-frequency analyses of oscillatory rhythms. In an early MEG study on five patients, the spike ECDs were localised to the same area as lower lip stimulation (Minami *et al.*, 1996). Subsequently, a study of seven cases reported spikes with an anterior positivity in the superior Rolandic (hand motor) region in four patients and in the inferior Rolandic (oromotor) region in three

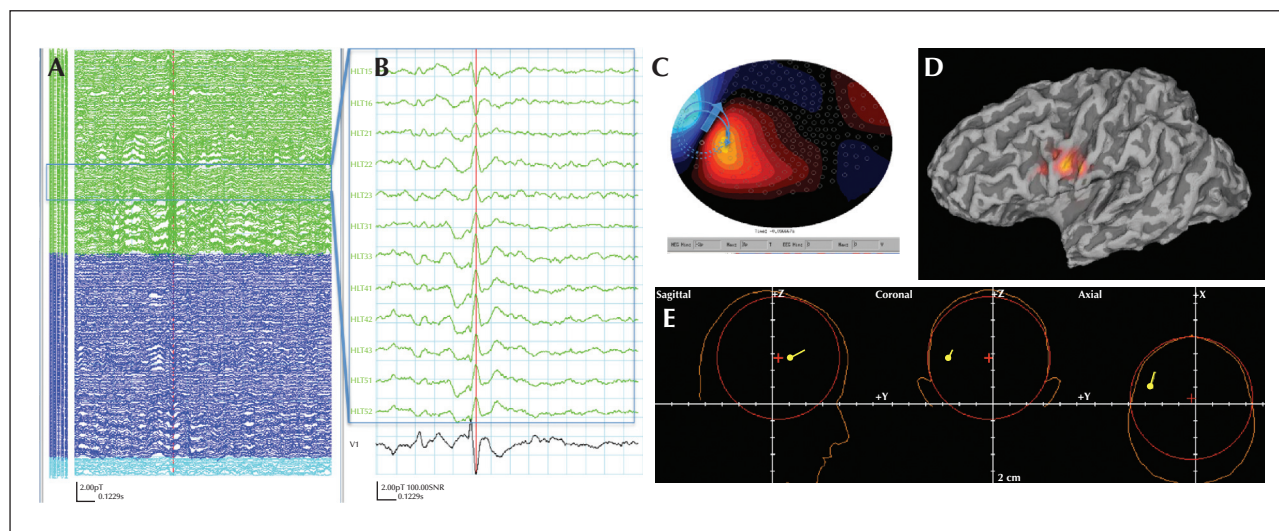


Figure 2. (A) MEG (275 channels) recording from an 11-year-old boy with BECTS. (B) Selected channels to illustrate the centro-temporal spike and lower trace, V1, and the virtual sensor electrode from the SAMg2 algorithm. (C) Flux potential and dipole illustration. (D) The synthetic aperture magnetometer (SAM) image overlaid onto the partially inflated 3D render of the structural MRI brain scan, showing the location in the inferior and anterior bank of the central sulcus. (E) The equivalent current dipole.

patients (Kamada *et al.*, 1998). The spike locations were related to seizure semiology, with orofacial seizure manifestations in patients with inferior Rolandic spikes and hand manifestations in those with superior Rolandic spikes. Increased fast wave activity was reported in five patients with neuropsychological deficits (Kamada *et al.*, 1998). In one case study, unilateral spikes localised to the bilateral operculum (Morikawa, 2000). Combining EEG/MEG source localisation and fMRI of tongue movements localised IEDs to the lower somatosensory cortex with co-located tongue movement fMRI activation (van der Meij *et al.*, 2001).

Later studies using whole head MEG localised IEDs 10–20 mm anterior and lateral to the hand somatosensory cortex (with concurrent median nerve stimulation) (Lin *et al.*, 2003a). Dipole analysis of bilateral discharges showed two ECD sources in homotopic motor areas (Lin *et al.*, 2003b). A single ECD accounted for most of the unilateral spikes in a pre-central location and over 98% of spikes were seen simultaneously on EEG and MEG, suggesting a stable tangential dipole source. For bilateral IED, the temporal difference between bilateral foci was 15–21 ms (Lin *et al.*, 2003a). The same group correlated the location of IED sources with sensory responses (Lin *et al.*, 2003b), finding IED sources closer to S2 than S1. Further analysis in the time frequency domain using Morlet Wavelets showed power increase in the 0.5 to 40-Hz range on the side of the spike (most prominent in the alpha band) and increase in the range of 0.5 to 25 Hz on the other homologous area of the other hemisphere (Lin *et al.*, 2006).

A study using the spatiotemporal multiple signal classification (MUSIC) analysis in five cases found that a single dipolar source was sufficient to account for the spiking activity in two cases, whereas in three cases, complex sources were resolved that started in the more superior areas (finger/hand) and propagated along the precentral sulcus to the mouth/tongue area (Huiskamp *et al.*, 2004). Based on a modest, but nevertheless larger series, in a study of 15 patients with benign epilepsy of childhood with centro-temporal spikes (BECTS), three main types of spikes according to ECD analysis were identified:

- superiorly oriented spike MEG dipoles in the opercular area;
- anteriorly oriented spike dipoles in the Rolandic area;
- laterally oriented spike dipoles in the interhemispheric area (Ishitobi *et al.*, 2005).

In perhaps the most detailed descriptive study of BECTS IED to date, using data from 17 patients, Pataraia *et al.* (2008) found spikes on the right in six, left in nine, and bilateral in two. Examination of isopotential and isofield maps over 250 ms before and after the maximum negative peak of the spike and using a PCA (Principal component analysis), as well as spatio-temporal dipole modelling, suggested that spikes were generated by a single tangential dipolar source located in the precentral gyrus, with the positive pole directed frontally and the negative pole directed centro-temporally. The dipole was stable over the entire (500-ms) time window analysed,

with no differences in spike location or orientation over time.

A correlation between cognitive deficits and spike location is described in 20 children with IFE whose scores on language tests decreased in the setting of left perisylvian spikes, and whose information processing was impaired in the setting of occipital spikes (Wolff *et al.*, 2005). No relationship between spike rate and psychological deficits was found (Wolff *et al.*, 2005). One publication reports MEG findings in Panayiotopoulos syndrome (PS) (Kanazawa *et al.*, 2005). Thirteen patients were studied with ECD analysis. Dipoles were localised along the parieto-occipital or calcarine sulcus in 11 of 13 patients and in the Rolandic area in two with atypical PS and Rolandic IEDs (Kanazawa *et al.*, 2005).

A few MEG studies have been reported on Landau-Kleffner syndrome (LKS) or CSWS, typically in conjunction with pre-surgical evaluation for multiple sub-pial transection. A study of four children with LKS found that the earliest spike activity originated in the intrasylvian cortex, spreading to contralateral sylvian cortex over 20 ms in one patient (Paetau *et al.*, 1999). Secondary spikes occurred within 10-60 ms in ipsilateral perisylvian, temporo-occipital, and parieto-occipital areas (Paetau *et al.*, 1999). Others have also reported more widespread spikes in LKS. In a study examining 19 patients, 13 had perisylvian MEG spikes, 10 had bilateral, three unilateral spike populations, and four also had non-sylvian spikes in frontal or parietal areas (Sobel *et al.*, 2000). In a larger cohort of 28 patients with LKS, 80% had bilateral epileptic discharges generated in the auditory and language-related perisylvian cortex, and approximately 20% had a unilateral perisylvian spike pacemaker that triggered secondary bilateral synchrony (Paetau, 2009). Based on an analysis of MEG alongside FDG positron emission tomography (PET) findings in six children with CSWS, spike-wave onset was shown to correspond to areas of PET hypermetabolism during wakefulness. This occurred in the superior temporal gyrus in LKS and centro-parietal regions in atypical Rolandic epilepsy. Areas of spike propagation predominantly showed PET hypermetabolism (De Tiege *et al.*, 2013).

Discussion

The analysis of MEG data described above shows that the ECD model produces plausible descriptions of the spike generators in IFEs, typically with a stable dipolar source. Some but not all studies successfully attempt to correlate spike source localisation with phenotypic features. MEG is an expensive technology, which does not easily lend itself to long recordings. There are, therefore, many more EEG studies in IFE that are covered elsewhere. Skull resistance and the sensitivity of the EEG to the conductivity

profile between the generators and electrodes introduce a blurring of the signal not seen in MEG. Until recently, most EEG studies have been limited to descriptions of signal semiology rather than descriptions of generators. A recent cross-sectional study of PS in which 76 children were followed for over two years (Ohtsu *et al.*, 2003) found that EEG foci frequently shift in location, multiply, and propagate diffusely over time, rather than remaining persistently localised to the occipital region. These changes in foci at the signal level cannot guarantee that there are equivalent changes in spike generators. It could be, for example, that the activity of dominant focal generators subsides and makes way for other generators to become prominent.

If a single or fixed number of ECDs are postulated, then the appropriate fixed single foci will be identified. Under these circumstances the modelling is judged to be successful if the solutions are plausible and the data fit well. This seems to be the case for Rolandic spikes. However, MUSIC analysis demonstrates that at least in some cases, a succession of generators is involved, even for Rolandic spikes (Huiskamp *et al.*, 2004). It might then appear that the results change depending on which method is used. In reality, each model has both limitations and the flexibility to allow for useful generalisations. For example, by allowing multiple and independent ECD solutions (for data from different times, periods, or subjects), the ECD model can provide a distribution of solutions rather than a single location, as was modelled in a comparison of 10 children with PS and 10 with other types of epilepsy (Yoshinaga *et al.*, 2006).

Our view of the relationship between MEG technology and epilepsy is slowly changing. Even in the cases in which a single focal generator dominates, the rest of the brain cannot be ignored. Discharges need to be explained not just in terms of changes within a local area, but as variations within a network (Richardson, 2012). To operate in this new framework, the ECD must be replaced by models that allow activity in different brain areas to be identified at different times and then used to delineate a network. SAM analysis offers distinct advantages while maintaining the computational simplicity of linear methods (Vrba and Robinson, 2001; Robinson *et al.*, 2004). The use of distributed source analysis is slowly gaining ground both for MEG (Grova *et al.*, 2008) and multichannel EEG (Dai *et al.*, 2012) analysis. It is even beginning to look possible that syndrome classification and some common aetiologies for epilepsy may be derived from source space analysis and subsequent network descriptions, especially if these descriptions allow for dynamically changing networks, which have so far been used for the description of network properties evoked by well-defined stimuli (Ioannides *et al.*, 2012).

Language impairment and idiopathic focal epilepsies

Anne de Saint-Martin and Caroline Seegmuller

When they described “mid temporal epilepsy” in 1954, Gibbs and Gibbs made specific reference to speech impairment in those children: “Non ictal speech disturbances are commoner in those patients; they may manifest themselves as attacks of speechlessness or aphasia, or as failure to learn to talk” (Gibbs *et al.*, 1954). Since then, a large amount of literature has been published about the cognitive, and more specifically, verbal deficits observed in “benign” epilepsy with centro-temporal spikes, or Rolandic epilepsy (BECTS/RE). Different mechanisms have been hypothesized about the interaction between language development and this age-related epilepsy with a perisylvian epileptogenic zone.

We reviewed the variety of speech and language impairments encountered in different types of Rolandic epilepsy. Indeed, the clinician may observe transient, acquired speech or language alterations in atypical or active forms of Rolandic epilepsy, more prolonged impairment of “high-level language” acquisition in typical forms, or, rarely, permanent severe speech dyspraxia associated with atypical forms. We also make reference to the association of centro-temporal spikes during sleep and specific language impairment.

Transient acquired speech or language impairment in atypical or active RE

Some children with atypical Rolandic epilepsy, or “active” Rolandic epilepsy with strong activation of spike and waves (SW) during sleep, may experience transient oromotor symptoms, such as perioral myoclonia (“spike-and-wave symptoms”), or oromotor hypotonia with drooling, slurred speech or dysarthria, mimicking sometimes a “pseudo-opercular syndrome”. These symptoms often fluctuate and may resolve after sleep EEG normalization (Deonna *et al.*, 1993). A longitudinal case study correlated these symptoms with the amount of bilateral SW during sleep, with a prominent opercular SW focus (de Saint-Martin *et al.*, 1999). Some of these atypical forms may evolve to an epileptic encephalopathy with continuous spike and waves (ECSWS or ESES), and more permanent symptoms.

The semiology of this acquired motor or expressive language impairment is completely different from both the acquired auditory and verbal agnosia and the receptive aphasia observed in Landau-Kleffner syndrome, associated with bitemporal continuous SW activity during sleep. Their mechanism, however, may

be similar. The various acquired verbal deficits appear to be directly correlated to the location and the intensity of the epileptic focus, during wakefulness and sleep, with a strong focal bilateral cortical inhibition (located in different language areas). Metabolic brain imaging performed during the active period of the epilepsy showed a marked focal hypermetabolism within a surrounding wide area of hypometabolism, suggesting a “remote inhibition” in distant cortical areas (Maquet *et al.*, 1995; De Tiege *et al.*, 2008). Urgent treatment modifications are often necessary to reduce the strong epileptic activation during sleep, in order to reverse acquired clinical symptoms.

Frequent “high-level language” impairment in typical RE

Heterogeneous cognitive deficits have been described since the 1990s in typical Rolandic epilepsy (RE), affecting both non-verbal cognitive functions (visual, executive, fine motor execution, attention, memory, and speed processing), and verbal functions during the active phase of the epilepsy (Weglage *et al.*, 1997; Metz-Lutz *et al.*, 1999). These are associated with a high frequency of learning disorders (10 to 40%) and academic underachievement (Pinton *et al.*, 2006; Piccinelli *et al.*, 2008; Smith *et al.*, 2015).

Many studies have focused on oral and written language skills and compared the performances of affected children to those of controls during the active phase, or after remission of the epilepsy. A language delay is more frequent in atypical RE versus typical forms. Typical RE children may have mild phonemic, semantic, auditory-verbal or lexical comprehension deficits revealed by accurate testing. These verbal deficits may impact reading, spelling, and learning, which are often impaired during the active phase of the epilepsy (Staden *et al.*, 1998; Carlsson *et al.*, 2000; Monjauze *et al.*, 2005; Northcott *et al.*, 2007; Riva *et al.*, 2007). They may also impact verbal knowledge and verbal reasoning or learning strategies. It is important to recall, however, that other cognitive deficits may interfere with language development and literacy learning, including deficits in executive function, short-term and long term verbal memory and attention, as well as variable degrees of hyperactivity, which is also frequently encountered in RE children during the active phase of the epilepsy (Chevalier *et al.*, 2000; Metz-Lutz and Filippini, 2006; Verrotti *et al.*, 2014).

Most of these studies are cross-sectional comparative studies and may not accurately capture the heterogeneity of these children, as some of them may function very well, and there is variability regarding individual cognitive evolution (Deonna *et al.*, 2000; Riva *et al.*, 2007). Moreover, in some children, specific

comorbid language learning disorders, specific language impairment (SLI), or dyslexia may precede the epilepsy.

Rolandic epilepsy, language network, interictal discharges and sleep

The question of the direct consequence of the perisylvian epileptic activity on language development, or the presence of an underlying common disorder of brain maturation remains unresolved.

Group studies show that a correlation between the type of cognitive deficits and the hemispheric location of the EEG is not self-evident (Nicolai *et al.*, 2006; Riva *et al.*, 2007). A recent comprehensive review performed by Overvliet emphasized the relationship between the intensity of cognitive deficits and the abundance of nocturnal epileptiform discharges (Overvliet *et al.*, 2010).

Evidence from behavioural investigations suggests an asymmetric response to dichotic listening in children with Rolandic epilepsy, correlated to the location of the epileptic focus (Metz-Lutz *et al.*, 1999; Bulgheroni *et al.*, 2008). Indeed, some authors hypothesized that the epileptic activity could “remodel” the language network. Small samples of functional imaging data shed some light on this hypothesis. fMRI analyses revealed that language-related activation was less lateralised to the left hemisphere in anterior brain regions in the RE patients, relative to the control group. This finding was consistent with decreased performance in the RE group compared to the control group on the neuropsychological measure of neuroanatomically anterior aspects of the language axis, namely, sentence production (Lillywhite *et al.*, 2009).

More recently, a study demonstrated that the functional connectivity between the resting-state network involving the Rolandic regions and the left inferior frontal gyrus (Broca’s area) was reduced in RE. This functional decoupling might be a clue to understand language impairment in typical RE and is in line with the identified neuropsychological profile of anterior language dysfunction (Besseling *et al.*, 2013b).

Recently, a deficit of declarative memory consolidation in a few RE and ESES patients was documented (Urbain *et al.*, 2011). In children with RE, non-REM sleep interictal epileptiform discharges (IED) may interfere in the dialogue between the temporal and frontal cortex, causing declarative memory deficits. The role of non-REM sleep interictal discharges acquires a special importance, due to their possible alteration of sleep homeostasis (Chevalier *et al.*, 2000; Bolsterli *et al.*, 2011). This could impact academic learning, notably high-level language and other cognitive acquisitions, during the epilepsy.

Speech dyspraxia and Rolandic epilepsy: a genetic comorbidity?

In the last few decades, there have been descriptions of both families and sporadic cases of atypical Rolandic epilepsy with co-occurrence of permanent severe language impairment (Scheffer *et al.*, 1995; Kugler *et al.*, 2008). In these families, different phenotypes were observed, from severe speech dyspraxia with cognitive impairment, to expressive dysphasia or even more mild language impairments. Some individuals experienced a worsening of impairments during the active phase of the epilepsy (Lesca *et al.*, 2013). In 2013, the results of three large genetic studies were published confirming the presence, in some cases, of a mutation in the *GRIN2A* gene, which encodes an NMDA receptor subunit; the cerebral expression of this gene is age related (Carvill *et al.*, 2013; Lemke *et al.*, 2013b; Lesca *et al.*, 2013). To better understand the role of this gene, more accurate descriptions of the clinical and neurophysiological phenotypes of the patients are being undertaken. Speech dyspraxia has also been demonstrated among typical children with RE, and the genetic locus for speech dyspraxia coincides with that for centro-temporal spikes on 11p13 (Pal *et al.*, 2010).

Specific language impairment and Rolandic spikes

Several authors have reported a higher incidence of nocturnal epileptiform EEG discharges in children with specific language impairment (SLI). Duvelleroy-Hommet described centro-temporal spike and waves (SW) on sleep EEGs in 24.3% of children with expressive SLI, as compared with 5.1% of children in a control group (Duvelleroy-Hommet *et al.*, 1995). Several studies have been performed showing between 14% and 40% interictal discharges during sleep in children with specific language impairment (Overvliet *et al.*, 2010). The benefit of antiepileptic drug treatment remains questionable, unless an intense sleep SW activation or an acquired regression has been documented (Picard *et al.*, 1998; Billard *et al.*, 2010).

Conclusion

Different types of speech and language impairments are observed in children with BECTS or RE. Some of these deficits are subtle, without any daily consequence; others can be severe and impact literacy development and verbal reasoning. In these children, specific developmental rehabilitation, and sometimes pharmacological adjustments are needed during the active phase of the epilepsy. Regular cognitive screening and environmental information are necessary during the follow-up of those children to reduce

academic or later social consequences. Different mechanisms undergird speech and language impairments, from comorbidities with a probable genetic substrate to direct consequences of the focal perisylvian epileptiform activity during sleep. Further research in genetics or on the consequences of disrupted sleep may enhance our understanding.

Co-occurring difficulties in Rolandic epilepsy: a focus upon attention

Anna B Smith

In Rolandic epilepsy (RE), seizures and focal interictal epileptiform discharges are in remission during or before adolescence. This syndrome is often coupled with deficits in literacy (Croona *et al.*, 1999; Lindgren *et al.*, 2004; Lundberg *et al.*, 2005; Monjauze *et al.*, 2005; Papavasiliou *et al.*, 2005; Northcott *et al.*, 2007; Staden *et al.*, 2007; Ay *et al.*, 2009; Clarke *et al.*, 2009; Tedrus *et al.*, 2009; Goldberg-Stern *et al.*, 2010; Smith *et al.*, 2012), language (Baglietto *et al.*, 2001; Monjauze *et al.*, 2005; Riva *et al.*, 2007; Volkl-Kernstock *et al.*, 2009; Verrotti *et al.*, 2010), and attention (Giordani *et al.*, 2006; Deltour *et al.*, 2007; Kavros *et al.*, 2008a; Cerminara *et al.*, 2010). The disorder is described as benign, but based upon the time course of childhood reading difficulties (Catts *et al.*, 2002) and attentional impairments (Spira and Fischel, 2005) in other patient populations, neuropsychological impairments may persist into later life. The following account focuses on the difficulties that children with RE experience in attention and how they might be linked with co-occurring literacy impairments.

Attentional processes are complex but can be broadly divided into approximately two categories. The first of these entails orienting to and detecting target stimuli amongst non-targets. Top down processing of targets is most commonly measured, where a response is required to a predefined target embedded within a stream of non-targets, typically using a continuous performance task (CPT) or a cancellation task (CT). Other most commonly utilised attention tasks involve a component of inhibition. Several tasks are available to measure subtle differences within executive function (EF), including: the stop task, in which a pre-potent response to “go” must be inhibited in response to rare “stop” signals which follow very closely behind these “go” signals; the stroop task, in which a frequent, congruent response must be suppressed in favour of an infrequent, incongruent one; the go/no-go task, in which a pre-potent signal to respond is interspersed with infrequent “no-go” signals; and switching or

shifting tasks, such as the Wisconsin Card Sorting Task, in which response rules are periodically changed throughout the task, requiring cognitive flexibility and a shift in engagement. Overarching most aspects of these EFs is the ability to sustain attention over a prolonged period (for more details of these tasks see Rubia *et al.* [2007]).

A systematic review of attention in children with RE (Kavros *et al.*, 2008b) brings together 14 studies of attention to examine the nature of the problem in this specific patient population. The majority of studies reviewed used either target detection tasks or tasks of inhibition, such as those outlined above, and found deficits where both of these kinds of tasks were used. More recent studies of attention in children with RE have added to this evidence (Giordani *et al.*, 2006; Deltour *et al.*, 2007; Cerminara *et al.*, 2010).

Our team has been exploring attention in children with RE and we present here some recent data from our lab. We have access to a large sample of children with RE and we have shown firstly that 20% of them have symptoms of ADHD, which is significantly greater than rates seen in the general population (Hernández-Vega *et al.*, 2014). Although it has been pointed out that a distinction should be made between a diagnosis of ADHD and the presence of attentional impairments (Cerminara *et al.*, 2010), it is clear that one of the hallmarks of children with ADHD is the presence of attentional deficits and furthermore, neurofunctional abnormalities during tasks of inhibition and attention have been found in this patient group (Smith *et al.*, 2006; Smith *et al.*, 2008) which correspond with attentional networks, particularly fronto-cingulate regions (Fan *et al.*, 2005). Secondly, in a study of the cognitive deficits seen in families with children with RE, we were able to confirm the findings from the systematic review that children with RE have deficits in target detection as measured by the CPT, and also that these deficits are present in their siblings unaffected by RE. This latter finding suggests that attentional difficulties are not explained by the presence of the seizures or spikes associated with RE. Instead, their presence in siblings unaffected by RE may be due to susceptibility factors shared between attentional deficits and RE.

We also wanted to know whether these attentional deficits were related to reading difficulties in our sample of 23 children with RE and their siblings. Although it is now well established that phonological processing is a strong predictor of reading success and that deficits in this domain explain the reading difficulties experienced by individuals with dyslexia (Snowling, 1995; Carroll and Snowling, 2004), attentional processes are likely to have an important role in reading. In typical readers, 10% of the variance associated with reading comprehension was explained by

attentional control, and was shown to be as important as phonological processing in predicting reading (Conners, 2009). However, the task used to measure attentional control in that study was a complex tracking task involving several automatic, as well as effortful, functions and, as such, not a pure measure of attention. Further analysis of our data (unpublished) shows that commission errors on our purer measure of attention (the CPT) correlate significantly with all literacy measures of the Gray Oral Reading Test, including reading rate ($r=0.63$; $p=0.002$), accuracy ($r=0.52$; $p=0.02$), fluency ($r=0.66$; $p=0.001$), and comprehension ($r=0.58$; $p=0.006$). These correlations suggest that in this albeit small sample of children with RE and their siblings, attention accounted for approximately one third of the variance associated with performance. The implication of these findings is that reading difficulties in children with RE may be underpinned by attentional deficits, which warrants further investigation.

Furthermore, given this strong association with attention and reading comprehension, it is possible that attentional training may have benefits for this patient group. This has not been extensively explored but evidence exists that attentional training can enhance several aspects of attentional function and behaviour in children with ADHD (Shalev *et al.*, 2007; Beck *et al.*, 2010) and furthermore, has been shown to improve literacy in this patient group (Shalev *et al.*, 2007).

In the light of these findings by our own team and others, a future goal should be to establish a comprehensive understanding of the neuropsychological deficits observed in children with RE with a large sample size. While attentional deficits are clearly present, the evidence remains less clear about literacy problems and whether attention is as important as phonological processing in predicting these difficulties. If this is the case, this population of children with RE may constitute a separate sub-group of poor readers.

Psychosocial aspects, parental reactions and needs in idiopathic focal epilepsies

Thalia Valeta

Our study aimed to document the psychosocial aspects of, parental reactions to, and needs associated with idiopathic focal epilepsies (IFE). The psychosocial effects of IFE on parents, their reactions, and needs, were assessed using a questionnaire that I specifically designed for this purpose. Out of 100 parents of children with epilepsy who completed the questionnaires, 22 were parents of children with IFE (Rolandic epilepsy,

Panayiotopoulos syndrome, and late-onset childhood occipital epilepsy of Gastaut). The questionnaire has good internal consistency. Parents of children with IFE expressed significant panic, fear, anxiety, shock, terror, and thoughts about death. Their sleep and quality of work were affected. The behaviour of half of the parents towards their children changed. Most of the parents expressed the need for education on epilepsies and psychological support for the child and themselves. They also expressed the need to participate in groups of parents with the same problem. This study is the first to provide detailed evidence that, despite the fact that IFE has an excellent prognosis, parental reactions are severe and their needs are significant and unmet. Completing the specifically designed questionnaire has given the parents space to reflect on their experience and express their feelings. The results inform physicians and consequently help to improve prevention and treatment outcome. The results of this study indicate that there is a need for family management, education, and psychological support for parents of children with IFE.

The psychosocial impact of epilepsy on affected children and their families is manifold with numerous and often synergistically interacting medical, psychological, economic, educational, personal, and social repercussions (Camfield, 2007; Valeta *et al.*, 2008; Valeta, 2010). The adjustment and other problems experienced by children with epilepsy and their parents have always been of concern to clinicians and healthcare providers. Understandably, attention and research has been primarily focused on severe epilepsies because of profound challenges in dealing with frequent and severe seizures, an endless quest for seizure control, and additional physical, social, and psychological problems.

Compared to other forms of epilepsy, the burden placed on the parents of children with IFEs, also known as benign childhood focal epilepsies (Panayiotopoulos *et al.*, 2008), has not been emphasized because of the comparative ease with which IFEs are medically managed and their comparatively better prognoses. Nevertheless, psychological research over the last decade (Valeta, 2005, 2011, 2012) has suggested that in children with IFE, parental attitudes and reactions are often severe and contrast with the physician's perception of these epilepsies as uncomplicated and benign conditions.

The purpose of this report is to show evidence that, despite their excellent prognosis, IFE represent a dramatic experience for the patients and the parents. The parents have significant and unmet needs that may affect the quality of their life, their parental role, and therefore the functioning of their children and the quality of life of the whole family.

Methods

My personal interest started in 2000, when talking extensively to parents of children with IFE; I was touched, impressed, and inspired by their experiences. I realised that they were concerned about many more issues other than the seizures themselves and those that they were able to discuss with their physician.

Consequently, I designed a questionnaire in order to:

- identify the parents' reactions and needs;
- identify the parents' feelings during and after the seizure;
- examine the relationship between the parents and their children after the event;
- examine how the event has affected their family;
- and identify its impact on the child's health, development, and future.

The initial questionnaire with the response of 15 parents of children with IFE in St. Thomas' Hospital was published in 2005 (Valeta, 2005).

Subsequently, in 2008, I initiated a study on parental reactions and needs of children with epilepsy in general. I modified and translated the questionnaire into Greek. The questionnaire, named "*Valeta Thalia Questionnaire for Parents of children with Epilepsy*"¹, has been validated and consists of 34 questions, of which 18 are qualitative and 16 quantitative. The questionnaire covers the following themes:

- parents' and children's demographic and clinical data;
- parental attitude, reaction and feelings during and after the seizures;
- parental experience to the medical examination;
- impact of seizures on parent-child relationship;
- impact of seizures on the family;
- parental reactions and attitude outside the family;
- parental reactions and attitude to antiepileptic drugs;
- parental needs other than medical.

Parents were recruited from the clinical practice at the department of Child Neurology, Agia Sophia Children's Hospital in Athens. Children with epilepsy were classified according to the ILAE classifications (Berg *et al.*, 2010). Out of 100 parents of children with epilepsy who completed the questionnaire, 22 were parents of children with IFE, comprising Rolandic epilepsy, Panayiotopoulos syndrome, and late-onset childhood occipital epilepsy of Gastaut.

For analysis of the open-ended questions, descriptive statistics were used (e.g. means, standard deviation, frequency, and % cumulative frequency). Data from the qualitative questions were processed via content

analysis methods. The parents' answers (raw data) were summarised in higher order themes in order to provide, in a more parsimonious manner, the participants' behaviour, reaction, and feelings, before, during and after a seizure. Reliability and internal consistency were 0.73 as measured using Cronbach's alpha, with inter-item correlations of 0.379, and corrected item total correlations of 0.355. The participants were given the opportunity to provide more than one answer in order to portray their experiences and express their feelings.

Results

The responses of the parents of children with IFE to the questionnaire provide interesting material on social and psychological issues. One quarter of parents reacted to their children's seizures in ways that are not medically recommended, or are potentially harmful, such as putting a spoon into the child's mouth, giving the child a bath, or lifting the child from the floor. To protect their children from social stigma or from bullying at school, parents discussed seizures with the child involved and the extended family more than with friends or the child's school. Half of the parents said that their behaviour towards the child had changed. They described becoming overprotective and less demanding in school performance. Some parent-child relationships became closer and some did not change. The following results from six representative questions illustrate the parental reactions and feelings during and after seizures, the effect that seizures have on everyday life and, finally, the parental needs of children with IFE. All the percentages are based on the answers/responses of the parents and not on the number of parents/participants.

– Feelings of parents during the seizure:

Negative feelings: fear, panic, terror: 37.5%; bad: 15.6%; anxiety: 9.4%; insecurity: 28.1%; guilt: 3.1%; thoughts about death: 6.3%; calm: 3.1%; denial: 3.1%. For this question, the results were dramatic because the feelings of nearly all the parents during the seizure were negative.

– Feelings of parents after the seizure:

Negative feelings: panic, fear, terror: 34%; anxiety: 31%; disappointment: 31.8%. Positive feelings: joy: 45%. Neutral feelings: secure under the doctor's care: 9.1%. Denial was expressed by 9.1%. For this question, panic, anxiety, and disappointment dominated. Some experienced joy and relief. The high percentage of joy and relief was due to the attack ending and the child recovering. During and after the event, we noticed parents expressing denial about a problem, which may have come from extreme fear.

Figure 3 shows the results for the question: "has the event influenced you in the following areas?" Figure 4

¹ Researchers who would like to use "Valeta Th. Questionnaire for Parents with Children with Epilepsy", please contact the author at: tvjoyflower@aol.com

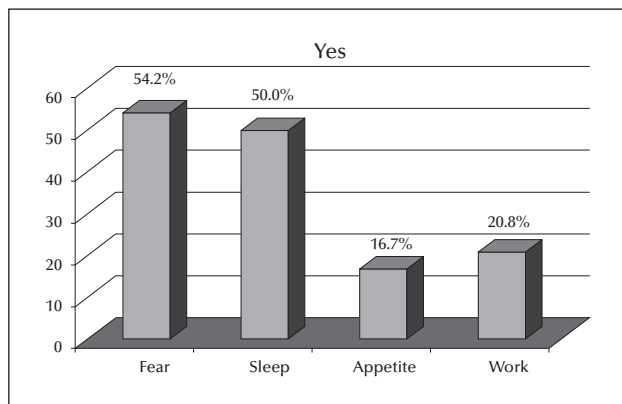


Figure 3. Results for the question: “has the event influenced you in the following areas?”

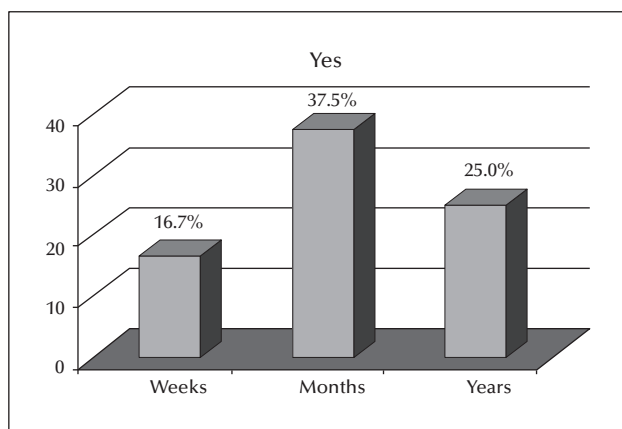


Figure 4. Results for the question: “how long has this lasted? years, months, weeks?”

shows the results for the question: “how long has this lasted? years, months, weeks?” The event affected parents mostly in that they were scared, and their sleep and quality of work was affected (*figure 3*), mostly for months, but for some years and others weeks (*figure 4*). *Figure 5* shows the results for the question: “do you need help other than medical?” *Figure 6* shows the results for the question: “do you need help in any of the following areas?”

The parents need help other than medical attention (*figure 5*), more specifically, education on epilepsies, psychological support for the child, parental support and advocacy groups, and psychological support for themselves (*figure 6*).

Discussion

This is the first study to provide quantitative and qualitative evidence that IFE has a dramatic impact on parents, with multiple emotional, psychological,

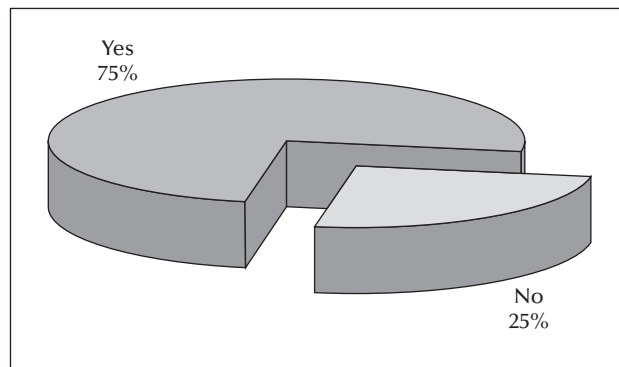


Figure 5. Results for the question: “do you need help other than medical?”

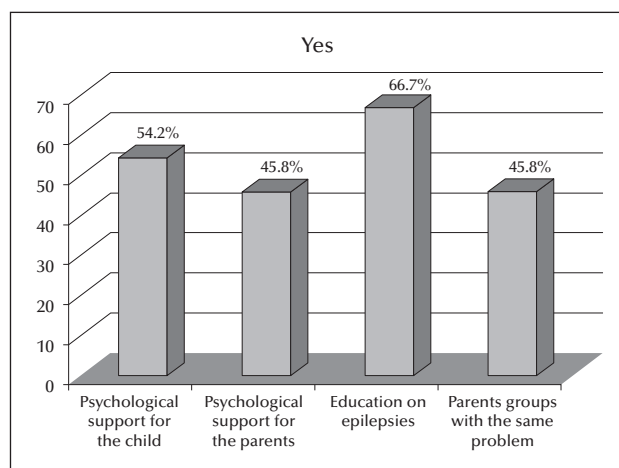


Figure 6. Results for the question: “do you need help in any of the following areas?”

social, and medical ramifications. As the results of this study show, this impact is much more severe than one would expect from a benign and self-limited condition. Unmet negative feelings of panic, fear, and thoughts about death, as mentioned in the results section, may affect the parents’ reactions and attitude and consequently their parental role, the functioning of their children, and the quality of life of the whole family. Thus, it is crucial that parents are given sufficient time and opportunity to discuss their concerns with specialists.

I suggest that health care professionals working with children who have IFE consider the following:

- Parents should be given general information about IFE and training to remain calm and confident about their children’s condition. Demonstrations of first aid practices for seizures are necessary.
- Educating parents about epilepsies and different types of seizure will help to alleviate the social stigma surrounding these conditions, which parents often pass on to their children.

– Parents who have watched their child during a seizure need specific information and psychological support to overcome anxiety, fear, panic, and other negative feelings, as detailed in the results of my study. This should be properly addressed from the time of first diagnosis, in order to improve the quality of life of the child and family.

– Anxiety and fear may result in overprotection, which interferes with parent/child separation and independence. Psychological support will help parents and patients, with coping techniques to manage stress, anger, anxiety or self-esteem. It can moderate parental perceptions of the child's illness and the marital strain related to the child's rearing, thus contribute to effective parenting.

I hope that the results of my study will assist the patient and parents, inform the physician, and, consequently, help to improve the treatment outcome.

Recent progress in the genetics of “idiopathic” childhood focal epilepsies

Gaetan Lesca, Gabrielle Rudolf, Pierre Szepietowski

So-called “idiopathic”, focal epilepsies of childhood are age-related epilepsy syndromes that mainly occur during critical developmental periods. Benign childhood epilepsy with centro-temporal spikes, or Rolandic epilepsy (BECTS/RE), is the most frequent form of childhood idiopathic focal epilepsies (IFE). Together with the Landau-Kleffner syndrome (also known as “acquired” epilepsy-aphasia) and the syndrome of continuous spike-and-waves during slow-wave sleep, RE exists on a single and continuous epilepsy-aphasia spectrum of childhood epileptic disorders with associated speech and language deficits. The pathophysiology has long been attributed to a complex interplay between brain development and maturation processes on the one hand and susceptibility genes on the other. Studies based on variable combinations of molecular cytogenetics, Sanger and next-generation DNA sequencing tools, and functional assays have led to the identification and validation of simple genetic mutations that can directly cause various types of childhood IFEs with variable degree of severity. The recent identification of *GRIN2A* defects in the epilepsy-aphasia spectrum represents a first step and makes significant progress in understanding underlying pathophysiological mechanisms.

While the relationships between RE and various comorbid conditions (e.g. migraine, cognitive and behavioural issues, or reading impairment) have recently been increasingly recognised, the association with transient or permanent speech and/or language

impairment has actually long been reported, including the identification of the genetic syndrome of RE with verbal dyspraxia (Scheffer *et al.*, 1995; Kugler *et al.*, 2008). The continuous spike-and-waves during slow-wave sleep syndrome (CSWS) and the Landau-Kleffner syndrome (LKS), also known as “acquired” epileptic aphasia, are two closely related epileptic encephalopathies (EEs) that represent more severe and less frequent forms of the IFE continuum. Indeed, each of these syndromes is now considered a different clinical expression of the same pathological spectrum (Rudolf *et al.*, 2009), which share the association of typically infrequent seizures with paroxysmal EEG discharges activated during drowsiness and sleep, and with more or less severe neuropsychological deficits.

A more modern view that takes into account the recent advances in determining the genetic origin of various types of epilepsies has recently challenged the classic distinction between idiopathic and symptomatic epilepsies (Berg *et al.*, 2010). For instance, it was unexpectedly demonstrated that EEs of various types, such as Dravet or Ohtahara syndromes, can have simple, monogenic causes (Depienne *et al.*, 2012; Epi4K Consortium *et al.*, 2013); conversely, epilepsies of genetic origin (formerly considered as idiopathic) can be associated with comorbid neurological conditions (e.g. migraine, behavioural or cognitive issues) or with structural lesions (e.g. cortical dysplasia). In the IFE, the possible existence of behavioural and cognitive issues, for instance, inherently challenged the use of the “idiopathic” term. It had long been assumed that in contrast to generalised epilepsies, most focal epilepsies are caused by lesions, infections, tumours, etc., and are under hardly any genetic influence. Twin studies and familial concurrences then indicated that focal epilepsies can also be sustained by genetic factors (Ryan, 1995). As an example, the mapping and the subsequent identification of the first “idiopathic epilepsy” gene (*CHRNA4*) encoding a nicotinic acetylcholine receptor subunit was obtained in autosomal dominant nocturnal frontal lobe epilepsy (ADNFLE) (Steinlein *et al.*, 1995; Berkovic *et al.*, 2006). Since then, several genes responsible for this and for other types of focal epilepsies have been identified.

Familial aggregation has long been recognised in RE (Neubauer *et al.*, 1998). Relatives of RE patients display a higher risk of epilepsy (notably RE, LKS or CSWS) than control individuals (De Tieghe *et al.*, 2006; Vears *et al.*, 2012; Dimassi *et al.*, 2014). Most RE, however, does not show simple inheritance. In recent years, one susceptibility gene for centro-temporal spikes in RE, *ELP4*, was proposed (Strug *et al.*, 2009) and rare mutations that might influence RE were identified in the paralogous *RBFOX1* and *RBFOX3* neuronal splicing regulators (Lal *et al.*, 2013a).

In contrast to RE, the genetic influence in LKS and CSWS has long remained controversial (Landau and Kleffner, 1957; De Tiege *et al.*, 2006; Rudolf *et al.*, 2009) and a role for autoimmunity was even hypothesized (Connolly *et al.*, 1999; Nieuwenhuis and Nicolai, 2006). Recent advances in molecular cytogenetics and next-generation DNA sequencing have dramatically helped in addressing this issue. Consistent with the existence of genomic defects (copy number variations) that may have possible pathophysiological influence in numerous human disorders including the epilepsies (Helbig *et al.*, 2009; Mefford *et al.*, 2010), the screening of a series of 61 patients with LKS or CSWS led to an overall picture with highly heterogeneous genomic architecture (Lesca *et al.*, 2012). A large number of potentially pathogenic alterations corresponded to genomic regions or genes (e.g. encoding cell adhesion proteins) that were either associated with the spectrum of autism disorders, or involved in speech or language impairment. This was of interest given the well-known association of LKS and CSWS spectrum with autistic-like manifestations (e.g. regression, disturbance of social interactions, perseveration) and language disorders. Particularly, the detection of several *de novo* genomic alterations in sporadic cases pointed to the possible role of several genes (Lesca *et al.*, 2012), including the NMDA glutamate receptor subunit gene *GRIN2A*, in LKS and CSWS.

Since then, the crucial and direct causal role of *de novo* or inherited *GRIN2A* mutations of various types (microdeletions, splice-site, nonsense, and missense mutations) in LKS, CSWS, and RE with verbal dyspraxia, has been demonstrated in three parallel studies (Carvill *et al.*, 2013; Lemke *et al.*, 2013b; Lesca *et al.*, 2013). It appears that up to 20% of disorders in this spectrum can be caused by simple defects in a single gene. An even more recent genomic study was performed at the milder end of the LKS/CSWS/RE spectrum; in a series of 47 patients with RE, one *GRIN2A* microdeletion and two 16p11.2 microduplications encompassing the *PRRT2* gene were identified (Dimassi *et al.*, 2014). *PRRT2* was recently shown to be involved in a wide range of paroxysmal neurological disorders, including infantile convulsions, paroxysmal dyskinesia (mostly kinesigenic), or hemiplegic migraine, which were variably associated (Cloarec *et al.*, 2012; Lee *et al.*, 2012). Interestingly, a p.Asn327Ser partial gain-of-glycosylation mutation in the Sushi repeat-containing *SRPX2* protein had been reported previously in a large family with RE, verbal dyspraxia, and intellectual disability (Roll *et al.*, 2006). The *SRPX2* gene is transcriptionally down-regulated by the so-called “speech gene”, *FOXP2* (Roll *et al.*, 2010), mutations in which can cause verbal dyspraxia (Lai *et al.*, 2001). Since then, it was shown that the p.Asn327Ser *SRPX2* dominant-negative mutation co-segregated with a

p.Ala716Thr *GLUN2A* (the protein product of the *GRIN2A* gene) missense mutation in most affected members of the same family (Lesca *et al.*, 2013). p.Asn327Ser was also detected in a few so-called control individuals according to the Exome Variant Server database (Piton *et al.*, 2013). On the one hand, those findings clearly challenged the direct causal role of this *SRPX2* mutation. On the other hand, the rat *SrpX2* knock-down *in utero* was shown to have dramatic consequences on neuronal migration in the developing rat cerebral cortex, and led to postnatal epileptiform activity that could be prevented early on by maternal administration of tubacin (Salmi *et al.*, 2013). Also, it was recently demonstrated that *SrpX2* influences synaptogenesis and vocalization in the mouse. Overall, *SRPX2* mutation might well be a strong genetic risk factor for neurodevelopmental disorders, including RE with verbal dyspraxia; in fact, a splice site *SRPX2* mutation was reported in one patient with autism (Lim *et al.*, 2013). As *GRIN2A* mutations unambiguously cause disorders of the epilepsy-aphasia spectrum, whether and how the *SRPX2* and *GRIN2A* products and related molecular networks would interfere with each other at the molecular and at the cellular levels at specific developmental stages emerges as an important question that surely deserves future investigations. Together with the future identification of other genetic and non-genetic factors involved in the spectrum of IFE, and of epilepsy-aphasia in particular, this will help in understanding the pathophysiology of this fascinating group of disorders situated at the crossroads of epileptic, cognitive, behavioural, and speech and language disorders.

Copy number variations in the idiopathic focal epilepsies

Ingo Helbig, Dennis Lal, Hiltrud Muhle, Bernd A Neubauer

Copy number variations (CNVs) are duplications or deletions of chromosomal segments. While structural genomic variation on a larger scale has been known to be the cause of rare genetic disorders for a long time, the abundance of variation on a submicroscopic scale came as a surprise to the field of genetic research. Up to 10% of the human genome is considered copy-number variable, i.e. deletions or duplications in these regions can be observed in healthy individuals (Itsara *et al.*, 2009). In addition, an increasing number of copy number variations are associated with neurodevelopmental disorders, including the idiopathic focal epilepsies (IFE) (Helbig *et al.*, 2009; de Kovel *et al.*, 2010; Mefford *et al.*, 2010; Reutlinger *et al.*, 2010). Amongst

the various microdeletions and microduplications, variations in the *GRIN2A* gene are strongly associated with electrical status epilepticus during slow-wave sleep (ESES), atypical benign partial epilepsy (ABPE), and Landau-Kleffner syndrome (LKS) (Reutlinger *et al.*, 2010; Carvill *et al.*, 2013; Lemke *et al.*, 2013b; Lesca *et al.*, 2013). To some extent, deletions encompassing the *GRIN2A* gene are also observed in less severe IFEs, *i.e.* typical Rolandic epilepsy. In this review, we summarise the current approaches regarding structural genomic variants, their relevance to neurodevelopmental disorders, and their role in the IFEs.

Copy number variations in the human genome

Copy number variations in the human genome fall into two big classes: recurrent copy number variants due to the underlying genomic architecture and non-recurrent deletion or duplication events (Itsara *et al.*, 2009). Recurrent structural genomic variants frequently arise due to the intricate architecture of the human genome, a complicated meshwork of deletions, duplications, and more complex rearrangements due to the recent evolutionary history of the species (Mefford and Eichler, 2009). These structural genomic features generate default breakpoints in the human genome through segmental duplications, particular small regions of the genome with a high degree of similarity ("microhomology") (Zhang *et al.*, 2009). During meiosis, a process referred to as non-allelic homologous recombination (NAHR) may result in the deletion or duplication of the interspersed genomic material (Shaw and Lupski, 2004). Depending on the size and gene composition of the interspersed region, deletions or duplications may result in neurodevelopmental disorders. These genomic hotspots, including microdeletions at 1q21.1, 15q13.3, 16p13.11, 16p11.2 and 15q11.2, are amongst the most frequent events found in neurodevelopmental disorders (Girirajan *et al.*, 2010; Cooper *et al.*, 2011). Homogeneous phenotypes due to deletions or duplications in genomic hotspots, such as Angelman syndrome, are referred to as genomic disorders (Lupski, 1998). Other rare deletion and duplication events encompass particular candidate genes, but are non-recurrent with different genomic breakpoints in each patient; deletions associated with human epilepsies include the 1q44 deletion and variations of the *SHANK3*, *NRXN1*, and *RBFOX1* genes (Caliebe *et al.*, 2010; Han *et al.*, 2013; Lal *et al.*, 2013a; Lal *et al.*, 2013b; Moller *et al.*, 2013).

Degrees of pathogenicity

By 2014, structural genomic variations were assessed on a routine clinical basis in tens of thousands of patients with intellectual disability and autism or

patients with syndromic features (Girirajan *et al.*, 2010; Cooper *et al.*, 2011). Also, large control datasets are available that allow researchers to assess possible findings against the normal variation in copy numbers in unaffected individuals. Given these unique and large datasets, it was possible to identify pathogenic structural genomic variants beyond the classic genomic disorders. Large datasets made it possible to identify structural genomic variants with variable penetrance and phenotypic heterogeneity, including the microdeletions 15q11.2, 15q13.3, and 16p13.11, and CNVs that were identified through a "genome first" strategy (Mefford *et al.*, 2008; Girirajan *et al.*, 2010), linking entirely unrelated phenotypes through common genetic findings that are absent in controls. The latter applies to the 1q21.1 microdeletion, which has also been identified in patients with IFEs (Mefford *et al.*, 2010).

Assessing pathogenicity

The high frequency of unique structural genomic variation in the human genome poses a difficulty when trying to assess the pathogenic role of a deletion or duplication identified in an individual patient (Conrad *et al.*, 2010). Even though cohort data suggest that groups of patients with neurodevelopmental disorders or various epilepsies have a significantly higher frequency of structural genomic variants than unaffected controls (Cooper *et al.*, 2011; Helbig *et al.*, 2013), the interpretation at the level of a single CNV might be difficult. In fact, most structural genomic variants identified in a given individual are likely to be transmitted from parents. This confounds the interpretation of the pathogenicity unless additional information can be taken into account. Accordingly, guidelines have been suggested for the interpretation of CNVs in patients with neurodevelopmental disorders (Miller *et al.*, 2010; Mefford *et al.*, 2011). For example, CNVs may be classified as pathogenic, likely pathogenic, or of unknown significance. Pathogenic CNVs are *de novo* deletions or deletions involving known epilepsy genes. Likely pathogenic CNVs are *de novo* duplications or any CNVs larger than 1 Mb of unknown inheritance. All other CNVs that have not been previously observed in controls and encompass genes are considered to be of unknown significance. This classification already implies that the interpretation of copy number variations in a clinical context is conservative, given the flood of unique and individual deletions and duplications in the human genome (Conrad *et al.*, 2010). With respect to the genetic architecture of human disease, copy number variations were the first example of rare genetic variants, foreshadowing many of the issues in the interpretation of rare genetic variants from current massive parallel sequencing studies.

CNVs in the idiopathic focal epilepsies

In the following, we aim to provide a list of *bona fide* CNV findings in IFEs, including the full spectrum of Rolandic epilepsy, atypical benign partial epilepsy, Landau-Kleffner syndrome, and electrical status epilepticus during slow-wave sleep. We have selected structural genomic variants reported in the literature based on the following criteria:

- a particular structural genomic variation or candidate gene encompassed by a structural genomic variation that has been observed at least twice in patients with IFE;
- or a particular CNV that has been observed at least once in a patient with IFE and additionally in patients with other neurodevelopmental disorders.

We have deliberately excluded structural genomic variants from this list that were only found once, as they constitute variants of unknown significance, the interpretation of which is difficult. This list of structural genomic variants includes various microdeletions at genomic hotspots and two candidate genes affected by non-recurrent exonic deletions.

Genomic hotspots in idiopathic focal epilepsies

Structural genomic variations at genomic hotspots were the first recurrent genetic risk factors identified for a common epilepsy syndrome, particularly idiopathic or genetic generalised epilepsy (IGE/GGE) (Dibbens et al., 2009; Helbig et al., 2009; de Kovel et al., 2010). Among the various hotspot deletions, the microdeletion at 15q13.3 assumes the most prominent role. The copy number variation can be found in up to 1% of patients with IGE/GGE, but is virtually absent in control cohorts. Other structural genomic variations that are prominent in IGE/GGE are the microdeletions 15q11.2 and 16p13.11 (de Kovel et al., 2010). These variants, however, represent moderate risk factors and are also identified in a significant subset of unaffected individuals. Other CNVs, including the microdeletions at 1q21.1, 16p11.2 and 22q11.2, and microduplications at 16p11.2, were identified in single patients (de Kovel et al., 2010; Mefford et al., 2010; Mefford et al., 2011; Dimassi et al., 2013). Microdeletions at 22q11.2 (Di George region) show some association with juvenile myoclonic epilepsy (Lemke et al., 2009; Helbig et al., 2013).

With respect to the IFEs, individual patients have been described with microdeletions at 1q21.1, 16p12.1, 16p13.11, and 15q13.3 (Mefford et al., 2010; Kevelam et al., 2012; Lesca et al., 2013). Given the known linkage of the 15q13.3 region to the EEG phenotype of centro-temporal spikes (Neubauer et al., 1998), the lack of 15q13.3 microdeletions in IFE compared to the relative abundance in generalised epilepsies is

astounding. However, this observation is congruent with the observed absence of 15q13.3 microdeletions in temporal lobe epilepsy (Heinzen et al., 2010). This suggests a novel phenotypic boundary that delineates 15q13.3 microdeletion-related phenotypes, such as IGE/GGE, autism, and intellectual disability, from other epilepsy phenotypes, particularly the non-lesional focal epilepsies. A single patient with ESES/CSWS has been described to carry a 15q13.3 microdeletion (Kevelam et al., 2012), which has so far not been reported in less severe phenotypes.

Candidate genes affected by non-canonical CNVs

GRIN2A

The *GRIN2A* gene has emerged as the major candidate gene for the IFEs. Reutlinger et al., first observed the association between *GRIN2A* and ESES/CSWS in three patients with larger, overlapping microdeletions (Reutlinger et al., 2010). The *GRIN2A* gene emerged as the only gene in the overlapping region in all three patients. Subsequently, further deletions and mutations were identified in *GRIN2A*, suggesting that this gene mutation is present in up to one third of patients with IFEs (Reutlinger et al., 2010; Carvill et al., 2013; Lemke et al., 2013b; Lesca et al., 2013). While the role of *GRIN2A* variation is not entirely clear in phenotypes at the more benign end of the IFE spectrum, the role in epilepsy-aphasia phenotypes, including ESES/CSWS and LKS, is uncontested. In fact, *GRIN2A* is one of the few genes implicated in human epilepsy that is found in a significant proportion of patients with a given phenotype, a role that is only paralleled by the importance of *SCN1A* mutations in Dravet syndrome (Hirose et al., 2013).

The *GRIN2A* gene encodes the NR2A subunit of the NMDA receptor, one of the main glutamate receptors in the central nervous system. At first glance, the involvement of *GRIN2A* in human epilepsy appears paradoxical, given that a gene dosage effect with reduced expression of the *GRIN2A* gene would reduce excitation rather than increase it. However, given the known interactions between NMDA receptor subunits, it can be speculated that the lack of *GRIN2A* is compensated by other subunits, such as the NR2B subunit, encoded by the *GRIN2B* gene. In particular, the NR2B subunit has different kinetics that might favour an overall increase in excitation. In addition, these subunits are regulated dynamically during development, providing a template that may account for the age-dependence of IFE phenotypes. The role of *GRIN2B* in human epilepsy is further corroborated by the recent identification of activating *GRIN2B* mutations in infantile spasms (Epi4K Consortium, 2013; Lemke et al., 2013a).

MDGA2

Lesca and collaborators described recurrent deletions affecting the *MDGA2* gene (Lesca *et al.*, 2012), coding for the MAM domain-containing glycosylphosphatidylinositol anchor protein 2. This protein represents a cell adhesion molecule, which is known to bind neuroligin 2, and regulates the development of inhibitory synapses (Lee *et al.*, 2013). While the *MDGA2* protein represents an interesting candidate protein, the interpretation of the genetic data demonstrates the complexity and difficulty in interpreting the pathogenic role of microdeletions against the river of rare, but benign variants. While larger deletions involving the *MDGA2* gene are absent in control populations, smaller deletions affecting only parts of the gene have been reported in control databases. While it is unclear whether these smaller deletions are real findings versus false positive database entries, this observation calls into question the pathogenic nature of *MDGA2* deletions. However, even though the rate of false positive findings in CNV databases is decreasing, some earlier studies using bacterial artificial chromosome (BAC) arrays have overestimated the size of CNVs in control populations. This may “mask” true pathogenic variants as has been observed previously for the 1q21.1 microdeletion (Sharp, 2009). Taken together, the study by Lesca and collaborators implies *MDGA2* deletions as a rare cause of ESES/CSWS, but the identification of further patients may help disperse remaining doubts.

Conclusion

The role of structural genomic variants came as a surprise to the field of epilepsy genetics and various studies suggest an attributable risk of up to 5% for larger deletions. Current *bona fide* structural genomic variants implicated in IFE include various genomic hotspot deletions, as well as microdeletions spanning the *GRIN2A* and *MDGA2* gene. With current, large-scale studies underway, the number of candidate CNVs for IFE and the proportion of patients with explanatory findings is likely to increase in the near future.

The genetics of centro-temporal sharp waves

Laura Addis, Lisa J. Strug, Deb K. Pal

Rolandic epilepsy (RE) or benign epilepsy with centro-temporal spikes (BECTS) is a common childhood neurodevelopmental disorder that is part of a phenotypic spectrum of idiopathic (genetic) focal epilepsies (IFEs). This spectrum encompasses RE, atypical benign

partial epilepsy (ABPE), Landau-Kleffner syndrome (LKS), and the most severe: epileptic encephalopathy with continuous spike-and-waves during slow-wave sleep (CSWS) (Gobbi *et al.*, 2006). All RE patients exhibit the defining electroencephalographic (EEG) abnormality of centro-temporal sharp waves (CTS), which can also be seen in other IFEs.

The onset of focal seizures in RE is frequently preceded in early childhood by various developmental deficits, including speech dyspraxia and impairments in language and literacy, and attention (Kavros *et al.*, 2008a; Smith *et al.*, 2012; Hernández-Vega *et al.*, 2015; Smith *et al.*, 2015). These neuropsychological deficits, as well as migraine, also cluster in families of RE patients who do not have epilepsy themselves (Clarke *et al.*, 2006; Strug *et al.*, 2012; Addis *et al.*, 2013). Both the seizures and the CTS spontaneously remit at adolescence, although the prognosis for the other neurodevelopmental problems is less favourable.

CTS is common (2-4%) in typically developing children of both genders (Eeg-Olofsson *et al.*, 1971), but is also observed with increased frequency in other developmental disorders, such as attention deficit hyperactivity disorder (ADHD) (Holtmann *et al.*, 2003; Holtmann *et al.*, 2006), specific language impairment (SLI) (Overvliet *et al.*, 2010), and autism (Ballaban-Gil and Tuchman, 2000). This suggests that CTS is not specific to epilepsy, but may be a marker of, or contributory factor to, more widespread neurodevelopmental abnormalities (Dooze *et al.*, 1996).

The common or typical form of RE appears to have a complex genetic inheritance. The genetic basis is, however, predominantly unknown, despite recent advances including identification of a low frequency of mutations (5% of cases) in the post-synaptic glutamate receptor subunit *GRIN2A* (Carvill *et al.*, 2013; Lemke *et al.*, 2013b; Lesca *et al.*, 2013); a cell growth regulator in the mTOR pathway, *DEPDC5* (Lal *et al.*, 2014); as well as potential new candidate genes, *RBFOX1* and *RBFOX3* (Lal *et al.*, 2013a).

Segregation analysis of the CTS trait in RE families clearly demonstrates autosomal dominant inheritance (Bali *et al.*, 2007). However, prior to these studies, the genetic basis of the disorder was debated due to differing criteria for case selection, preference for densely affected pedigrees, and EEG measurement and other confounders such as age of subjects, which may have increased genetic heterogeneity (Bali *et al.*, 2007). In a *candidate* gene study of neuronal nicotinic acetylcholine receptor (*AChR*) genes in 22 families multiplex for RE and two for ABPE, CTS was found to link to 15q14 with a multipoint LOD score of 3.56 (Neubauer *et al.*, 1998). However, this locus has never been replicated, and updated genomic maps realign this region to 15q13.33, a hotspot for recurrent CNVs.

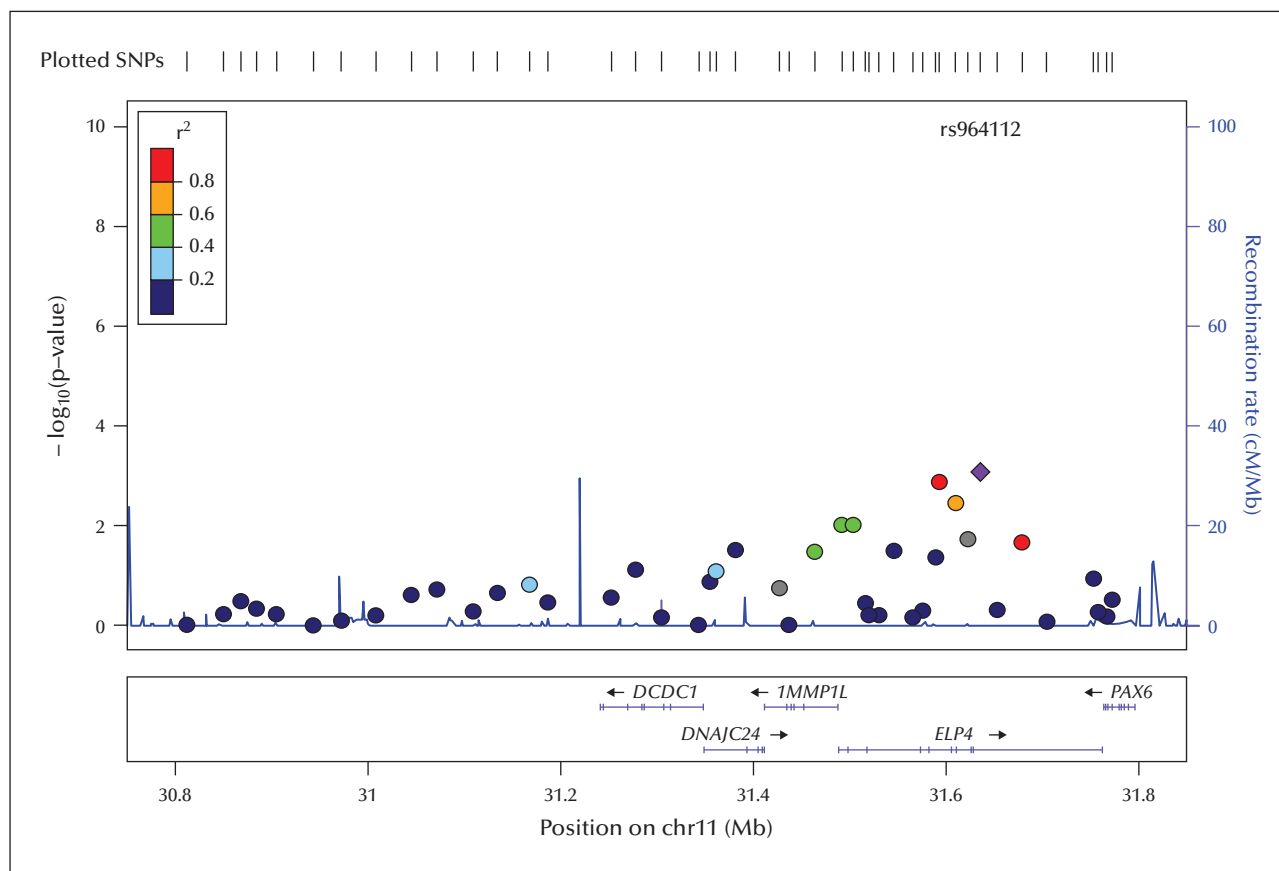


Figure 7. A plot of the association evidence for CTS in the chromosome 11p13 region (NCBI build 36, LocusZoom viewer). Colours represent HapMap CEU linkage disequilibrium r^2 with the most significant SNPs, rs964112 as the purple diamond, and rs986527 as the most proximal red circle.

A genome-wide linkage study for CTS in singly ascertained RE families identified strongly linked markers in a region of chromosome 11p13 with a maximum heterogeneity LOD of 4.3 (Strug *et al.*, 2009). Both European and non-European ancestry families contributed proportionally to the LOD score at this locus. Forty-four single nucleotide polymorphisms (SNPs) were typed across the linked region over six genes; *DCDC5*, *DCDC1*, *DPH4*, *IMMP1L*, *ELP4*, and *PAX6*, and significant evidence of association was found with three intronic SNPs in the gene *ELP4*. This association with the same alleles and direction of effect was replicated in a second independent sample within this study. The markers rs986527 in intron 5 and rs964112 in intron 9 of *ELP4* provided the strongest association evidence in the joint analysis ($p=0.0002$; figure 7).

Interestingly, a subsequent study has shown a pleiotropic effect of the 11p13 locus on speech dyspraxia and CTS in families singly ascertained on the basis of RE. Evidence for linkage to this locus increased substantially to HLOD 7.5 from 4.3 at D11S914, the same marker linked for CTS alone (Pal *et al.*, 2010). As speech dyspraxia precedes the appearance of CTS

by approximately four years, and siblings can have speech dyspraxia but no CTS, it is unlikely that CTS is causal for the speech problems, although the spontaneous EEG discharges could potentially exacerbate the speech impairment. The comparison of variants in *ELP4* in siblings without RE themselves, but who have CTS or verbal dyspraxia, may potentially uncover if variants in *ELP4* that associate with CTS are also associated with verbal dyspraxia.

So far, the linkage and association results implicate variants in the *ELP4*-*PAX6* region, and both genes make attractive candidates. *ELP4* is one of six subunits of the Elongator complex, an incompletely characterised protein located with different functionality in both the nucleus (transcript elongation and gene expression) and cytoplasm (exocytosis and tRNA modification) (Otero *et al.*, 1999; Svejstrup, 2007). There is increasing evidence that Elongator is involved in several different neurological disorders (reviewed in Nguyen *et al.* [2009]). It is believed to play an important role in the transcription of genes that regulate the actin cytoskeleton and cell migration. Mutations in *ELP1* cause familial dysautonomia (Slaugenhaupt *et al.*,

2001), a neurodevelopmental autonomic neuropathy that also includes EEG abnormalities and seizures, (Niedermeyer *et al.*, 1967), while *ELP3* variants are associated with motor neuron disease (Simpson *et al.*, 2009). Sequencing of the coding and promoter regions of *ELP4* in RE cases failed to identify any mutations or enrichment of polymorphisms, indicating that the effector may lie in the non-coding regions of this gene. Due to a drop off in linkage disequilibrium, it is less likely that the causal variants reside in the coding regions of neighbouring genes *PAX6* and *IMMP1L* (Strug *et al.*, 2009). Interestingly, the intronic regions between exons 9 and 12 of *ELP4* are large and ultraconserved. These regions contain long-range *cis* regulatory enhancers for downstream *PAX6*, which are tissue- or developmental stage-specific in their expression (McBride *et al.*, 2011).

PAX6 is a transcription factor crucial for normal development of the eyes, spinal cord, several areas of the brain, and other organs (Griffin *et al.*, 2002). Deletions of *PAX6* with *WT1* cause Wilms tumour, aniridia, genital anomalies, and intellectual disability (WAGR syndrome). A rare case of duplication of *PAX6* and the last two exons/introns of *ELP4* has been reported with fronto-temporal neonatal seizures, developmental delay, microcephaly, and minor ocular findings (Aradhya *et al.*, 2011), indicating *PAX6* rearrangements or mutations could also be responsible for neuronal hyperexcitability. *PAX6* has recently been proposed as the foremost transcription factor governing glutamatergic neuronal differentiation. Overexpression of *Pax6* during rat brain development induced dysregulated glutamatergic neuronal differentiation, increased expression of glutamate transporters, and reduced seizure thresholds and autistic-like behaviour, which was reversed on treatment with a glutamate receptor antagonist (Kim *et al.*, 2014). Therefore, functional evidence, from the dysregulation of *PAX6* and its link via the glutamatergic neurotransmission system with *GRIN2A*, makes it a prime candidate for involvement in CTS.

Future work on the *ELP4-PAX6* locus will need to involve deep sequencing of all variation across the region, including non-coding regions, in both cases and controls, in order to identify alleles that are more frequent and potentially increase the risk for CTS. Additional work will identify which gene is implicated in CTS and by what mechanism. If identified variants fall within known enhancer or promoter regions for example, then functional work can ascertain their effects on gene expression in model systems. Substantiating a gene in this region as a risk locus for CTS is another step towards understanding the complex genetic model of RE. Although CTS is common in children (Eeg-Olofsson *et al.*, 1971), only 10% with CTS manifest clinical seizures, indicating there must be

additional genetic factors acting in combination with susceptibility variants in this region to cause either the classic focal seizures of RE, or the other common comorbidities. □

Supplementary data.

Summary didactic slides are available on the www.epilepticdisorders.com website.

Acknowledgements and disclosures.

- The work of A. Ioannides was partially funded by the European Commission under the Seventh Framework Programme (FP7/2007-2013) with grant ARMOR, agreement number 287720.
 - K. Hamandi has received funding from the Waterloo Foundation for BECTS Imaging Research and is supported by Cardiff and Vale University Health Board and the National Institute for Health and Social Care Research, Welsh Government.
 - The work on *Recent progress in the genetics of “idiopathic” childhood focal epilepsies* by G. Lesca, G. Rudolf and P. Szepietowski was supported by ANR (Agence Nationale de la Recherche) grant “EPILAND” (ANR-2010-BLA01 “N-1405 01”) with EuroBiomed label, National PHRC grant 2010 N° 03-08, by the European Union Seventh Framework Programme FP7/2007-2013 under the project DESIRE (grant agreement n°602531), and INSERM (Institut National de la Santé et de la Recherche Médicale).
 - The work on *The genetics of centro-temporal sharp waves* by L. Addis, LJ Strug and DK Pal was supported by the National Institutes of Health (NS04750), the European Research Commission through Marie Curie Award, and the Waterloo Foundation.
- All authors have no conflicts of interest to disclose.
When financial support for related studies was received this is disclosed at the Acknowledgments section.

References

- Addis L, Chiang T, Clarke T, *et al.* Evidence for linkage of migraine in Rolandic epilepsy to known 1q23 FHM2 and novel 17q22 genetic loci. *Genes Brain Behav* 2013; 13(3): 333-40.
- Aicardi J. Atypical semiology of Rolandic epilepsy in some related syndromes. *Epileptic Disord* 2000; 2(1): S5-9.
- Aicardi J, Chevrie JJ. Atypical benign partial epilepsy of childhood. *Dev Med Child Neurol* 1982; 24(3): 281-92.
- Ambrosetto G, Tassinari CA. Antiepileptic drug treatment of benign childhood epilepsy with Rolandic spikes: is it necessary? *Epilepsia* 1990; 31(6): 802-5.
- Aradhya S, Smaoui N, Marble M, Lacassie Y. De novo duplication 11p13 involving the *PAX6* gene in a patient with neonatal seizures, hypotonia, microcephaly, developmental disability and minor ocular manifestations. *Am J Med Genet A* 2011; 155A(2): 442-4.
- Avanzini G, Manganotti P, Meletti S, *et al.* The system epilepsies: a pathophysiological hypothesis. *Epilepsia* 2012; 53(5): 771-8.
- Ay Y, Gokben S, Serdaroglu G, *et al.* Neuropsychologic impairment in children with Rolandic epilepsy. *Ped Neurol* 2009; 41(5): 359-63.

- Baglietto MG, Battaglia FM, Nobili L, et al. Neuropsychological disorders related to interictal epileptic discharges during sleep in benign epilepsy of childhood with centrotemporal or Rolandic spikes. *Dev Med Child Neurol* 2001; 43(06): 407-12.
- Bali B, Kull L, Strug L, et al. Autosomal dominant inheritance of centrotemporal sharp waves in Rolandic epilepsy families. *Epilepsia* 2007; 48(12): 2266-72.
- Ballaban-Gil K, Tuchman R. Epilepsy and epileptiform EEG: association with autism and language disorders. *Ment Retard Dev Disabil Res Rev* 2000; 6(4): 300-8.
- Beaumanoir A, Nahory A. Benign partial epilepsies: 11 cases of frontal partial epilepsy with favorable prognosis. *Rev Electroencephalogr Neuropsychiol Clin* 1983; 13(3): 207-11.
- Beaussart M. Benign epilepsy of children with Rolandic (centro-temporal) paroxysmal foci: a clinical entity. Study of 221 cases. *Epilepsia* 1972; 13: 795-811.
- Beck SJ, Hanson CA, Puffenberger SS, Benninger KL, Benninger WB. A controlled trial of working memory training for children and adolescents with ADHD. *J Clin Child Adolesc Psychol* 2010; 39(6): 825-36.
- Berg AT, Berkovic SF, Brodie MJ, et al. Revised terminology and concepts for organization of seizures and epilepsies: report of the ILAE Commission on Classification and Terminology, 2005-2009. *Epilepsia* 2010; 51(4): 676-85.
- Berkovic SF, Mulley JC, Scheffer IE, Petrou S. Human epilepsies: interaction of genetic and acquired factors. *Trends Neurosci* 2006; 29(7): 391-7.
- Besseling RM, Jansen JF, Overvliet GM, et al. Reduced structural connectivity between sensorimotor and language areas in Rolandic epilepsy. *PLoS One* 2013a; 8(12): e83568.
- Besseling RM, Jansen JF, Overvliet GM, et al. Reduced functional integration of the sensorimotor and language network in Rolandic epilepsy. *Neuroimage Clin* 2013b; 2: 239-46.
- Billard C, Hassairi I, Delteil F. Specific language impairment and electroencephalogram: which recommendations in clinical practice? A cohort of 24 children. *Arch Pediatr* 2010; 17(4): 350-8.
- Bolsterli BK, Schmitt B, Bast T, et al. Impaired slow wave sleep downscaling in encephalopathy with status epilepticus during sleep (ESES). *Clin Neurophysiol* 2011; 122(9): 1779-87.
- Braakman HM, Vaessen MJ, Hofman PA, et al. Cognitive and behavioral complications of frontal lobe epilepsy in children: a review of the literature. *Epilepsia* 2011; 52(5): 849-56.
- Bulgheroni S, Franceschetti S, Vago C, et al. Verbal dichotic listening performance and its relationship with EEG features in benign childhood epilepsy with centrotemporal spikes. *Epilepsy Res* 2008; 79(1): 31-8.
- Caliebe A, Kroes HY, van der Smagt JJ, et al. Four patients with speech delay, seizures and variable corpus callosum thickness sharing a 0.440 Mb deletion in region 1q44 containing the HNRPU gene. *Eur J Med Genet* 2010; 53(4): 179-85.
- Camfield PR. Problems for people with epilepsy beyond seizures. *Epilepsia* 2007; 48(S9): 1-2.
- Capovilla G, Beccaria F, Montagnini A. 'Benign focal epilepsy in infancy with vertex spikes and waves during sleep'. Delimitation of the syndrome and recalling as 'benign infantile focal epilepsy with midline spikes and waves during sleep' (BIMSE). *Brain Dev* 2006; 28(2): 85-91.
- Capovilla G, Berg AT, Cross JH, et al. Conceptual dichotomies in classifying epilepsies: Partial versus generalized and idiopathic versus symptomatic (April 18-20, 2008, Monreale, Italy). *Epilepsia* 2009a, Ahead of print.
- Capovilla G, Striano P, Beccaria F. Changes in Panayiotopoulos syndrome over time. *Epilepsia* 2009b; 50(S5): 45-8.
- Capovilla G, Beccaria F, Bianchi A, et al. Ictal EEG patterns in epilepsy with centro-temporal spikes. *Brain Dev* 2011; 33(4): 301-9.
- Capovilla G, Moshe SL, Wolf P, Avanzini G. Epileptic encephalopathy as models of system epilepsy. *Epilepsia* 2013; 54(S8): 34-7.
- Caraballo R, Fontana E, Michelizza B, et al. Carbamazepina, assenze atipiche, crisi atoniche e stato di PO continua del sonno (POCS). *Bolletina della lega italiana contro l'epilessia* 1989; 66/67: 379-81.
- Caraballo RH, Cersosimo RO, Espeche A, Fejerman N. Benign familial and non-familial infantile seizures: a study of 64 patients. *Epileptic Disord* 2003; 5(1): 45-9.
- Caraballo R, Cersosimo R, Capovilla G, Fejerman N. Benign focal seizures of adolescence. In: Fejerman N, Caraballo R. *Benign focal epilepsies in infancy, childhood and adolescence*. Montrouge: John Libbey, 2007a: 243-51.
- Caraballo R, Cersosimo R, Fejerman N. Panayiotopoulos syndrome: a prospective study of 192 patients. *Epilepsia* 2007b; 48(6): 1054-61.
- Caraballo R, Cersosimo R, Fejerman N. Symptomatic focal epilepsies imitating atypical evolutions of idiopathic focal epilepsies in childhood. In: Fejerman N, Caraballo R. *Benign focal epilepsies in infancy, childhood and adolescence*. Montrouge: John Libbey, 2007c: 221-39.
- Caraballo RH, Cersosimo RO, Fejerman N. Childhood occipital epilepsy of Gastaut: a study of 33 patients. *Epilepsia* 2008; 49(2): 288-97.
- Caraballo RH, Cersosimo R, De los Santos C. Levetiracetam-induced seizure aggravation associated with continuous spikes and waves during slow sleep in children with refractory epilepsies. *Epileptic Disord* 2010; 12(2): 146-50.
- Caraballo RH, Aldao Mdel R, Cachia P. Benign childhood seizure susceptibility syndrome: three case reports. *Epileptic Disord* 2011; 13(2): 133-9.
- Carlsson G, Igelbrink-Schulze N, Neubauer BA, Stephani U. Neuropsychological long-term outcome of Rolandic EEG traits. *Epileptic Disord* 2000; 2(S1): S63-6.
- Carroll JM, Snowling MJ. Language and phonological skills in children at high risk of reading difficulties. *J Child Psychol Psychiatry* 2004; 45(3): 631-40.
- Carvill GL, Regan BM, Yendle SC, et al. GRIN2A mutations cause epilepsy-aphasia spectrum disorders. *Nat Genet* 2013; 45(9): 1073-6.

- Catania S, Cross H, de Sousa C, Boyd S. Paradoxical reaction to lamotrigine in a child with benign focal epilepsy of childhood with centrotemporal spikes. *Epilepsia* 1999;40(11):1657-60.
- Catts HW, Fey ME, Tomblin JB, Zhang X. A longitudinal investigation of reading outcomes in children with language impairments. *J Speech Lang Hear Res* 2002;45(6):1142.
- Cerminara C, D'Agati E, Lange KW, et al. Benign childhood epilepsy with centrotemporal spikes and the multicomponent model of attention: A matched control study. *Epilepsy & Behav* 2010;19(1):69-77.
- Chevalier H, Metz-Lutz MN, Segalowitz SJ. Impulsivity and control of inhibition in Benign Focal Childhood Epilepsy (BFCE). *Brain Cogn* 2000;43(1-3):86-90.
- Clarke T, Bali B, Carvalho J, et al. Speech and language disorders aggregate in Rolandic epilepsy families. *Neuropediatrics* 2006;37(S1):60.
- Clarke T, Baskurt Z, Strug LJ, Pal DK. Evidence of shared genetic risk factors for migraine and Rolandic epilepsy. *Epilepsia* 2009;50(11):2428-33.
- Cloarec R, Bruneau N, Rudolf G, et al. PRRT2 links infantile convulsions and paroxysmal dyskinesia with migraine. *Neurology* 2012;79(21):2097-103.
- Cole AJ, Andermann F, Taylor L, et al. The Landau-Kleffner syndrome of acquired epileptic aphasia: unusual clinical outcome, surgical experience, and absence of encephalitis. *Neurology* 1988;38(1):31-8.
- Connors FA. Attentional control and the simple view of reading. *Reading and Writing* 2009;22:591-613.
- Connolly AM, Chez MG, Pestronk A, Arnold ST, Mehta S, Deuel RK. Serum autoantibodies to brain in Landau-Kleffner variant, autism, and other neurologic disorders. *J Pediatr* 1999;134(5):607-13.
- Conrad DF, Pinto D, Redon R, et al. Origins and functional impact of copy number variation in the human genome. *Nature* 2010;464(7289):704-12.
- Cooper GM, Coe BP, Girirajan S, et al. A copy number variation morbidity map of developmental delay. *Nat Genet* 2011;43(9):838-46.
- Covanis A, Lada C, Skiadas K. Children with Rolandic spikes and ictal vomiting: Rolandic epilepsy or Panayiotopoulos syndrome? *Epileptic Disord* 2003;5(3):139-43.
- Croona C, Kihlgren M, Lundberg S, Eeg-Olofsson O, Eeg-Olofsson KE. Neuropsychological findings in children with benign childhood epilepsy with centrotemporal spikes. *Dev Med Child Neurol* 1999;41(12):813-8.
- Dai Y, Zhang W, Dickens DL, He B. Source connectivity analysis from MEG and its application to epilepsy source localization. *Brain Topogr* 2012;25(2):157-66.
- Datta A, Sinclair DB. Benign epilepsy of childhood with Rolandic spikes: typical and atypical variants. *Pediatr Neurol* 2007;36(3):141-5.
- de Kovel CG, Trucks H, Helbig I, et al. Recurrent microdeletions at 15q11.2 and 16p13.11 predispose to idiopathic generalized epilepsies. *Brain* 2010;133(1):23-32.
- de Marco P, Tassinari CA. Extreme somatosensory evoked potential (ESEP): an EEG sign forecasting the possible occurrence of seizures in children. *Epilepsia* 1981;22(5):569-75.
- de Saint-Martin A, Petiau C, Massa R, et al. Idiopathic Rolandic epilepsy with interictal facial myoclonia and oromotor deficit: a longitudinal EEG and PET study. *Epilepsia* 1999;40(5):614-20.
- De Tiege X, Goldman S, Verheulpen D, Aeby A, Poznanski N, Van Bogaert P. Coexistence of idiopathic Rolandic epilepsy and CSWS in two families. *Epilepsia* 2006;47(10):1723-7.
- De Tiege X, Ligot N, Goldman S, Poznanski N, de Saint Martin A, Van Bogaert P. Metabolic evidence for remote inhibition in epilepsies with continuous spike-waves during sleep. *Neuroimage* 2008;40(2):802-10.
- De Tiege X, Trotta N, Op de Beeck M, et al. Neurophysiological activity underlying altered brain metabolism in epileptic encephalopathies with CSWS. *Epilepsy Res* 2013;105(3):316-25.
- Deltour L, Quaglini V, Barathon M, De Broca A, Berquin P. Clinical evaluation of attentional processes in children with benign childhood epilepsy with centrotemporal spikes (BCECTS). *Epileptic Disorders* 2007;9(4):424-31.
- Deonna T. Annotation: cognitive and behavioural correlates of epileptic activity in children. *J Child Psychol Psychiatry* 1993;34(5):611-20.
- Deonna T, Roulet-Perez E. Early-onset acquired epileptic aphasia (Landau-Kleffner syndrome, LKS) and regressive autistic disorders with epileptic EEG abnormalities: the continuing debate. *Brain Dev* 2010;32(9):746-52.
- Deonna TW, Roulet E, Fontan D, Marcoz JP. Speech and oromotor deficits of epileptic origin in benign partial epilepsy of childhood with Rolandic spikes (BPERS). Relationship to the acquired aphasia-epilepsy syndrome. *Neuropediatrics* 1993;24(2):83-7.
- Deonna T, Zesiger P, Davidoff V, Maeder M, Mayor C, Roulet E. Benign partial epilepsy of childhood: a longitudinal neuropsychological and EEG study of cognitive function. *Dev Med Child Neurol* 2000;42(9):595-603.
- Depienne C, Gourfinkel-An I, Baulac S. Genes in infantile epileptic encephalopathies. In: Noebels J, Avoli M, Rogawski MA, Olsen RW, Delgado-Escueta AV. *Jasper's basic mechanism of the epilepsies*. Bethesda (MD): National Center for Biotechnology Information, 2012: 1-19.
- Dibbens LM, Mullen S, Helbig I, et al. Familial and sporadic 15q13.3 microdeletions in idiopathic generalized epilepsy: precedent for disorders with complex inheritance. *Hum Mol Genet* 2009;18(19):3626-31.
- Dimassi S, Labalme A, Lesca G, et al. A subset of genomic alterations detected in Rolandic epilepsies contains candidate or known epilepsy genes including GRIN2A and PRRT2. *Epilepsia* 2013;55(2):370-8.
- Doose H, Neubauer B, Carlsson G. Children with benign focal sharp waves in the EEG-developmental disorders and epilepsy. *Neuropediatrics* 1996;27(5):227-41.

Duvelleroy-Hommet C, Billard C, Lucas B, et al. Sleep EEG and developmental dysphasia: lack of a consistent relationship with paroxysmal EEG activity during sleep. *Neuropediatrics* 1995; 26(1): 14-8.

Eeg-Olofsson O, Petersen I, Sellden U. The development of the electroencephalogram in normal children from the age of 1 through 15 years. Paroxysmal activity. *Neuropadiatrie* 1971; 2(4): 375-404.

Engel F Jr. Report of the ILAE classification core group. *Epilepsia* 2006; 47(9): 1558-68.

Epi4K Consortium, Epilepsy Phenome/Genome Project, Allen AS, et al. De novo mutations in epileptic encephalopathies. *Nature* 2013; 501(7466): 217-21.

Fan J, McCandliss BD, Fossella J, Flombaum IJ, Posner MI. The activation of attentional networks. *Neuroimage* 2005; 26(3): 471-9.

Fejerman N. Atypical evolutions of benign partial epilepsies in children. *Int Pediatr* 1996; 11(6): 351-6.

Fejerman N. Benign childhood epilepsy with centrotemporal spikes. In : Engel J, Pedley TA. *Epilepsy. A comprehensive textbook*. Philadelphia: Lippincott, Williams & Wilkins, 2008: 2369-78.

Fejerman N, Di Blasi AM. Status epilepticus of benign partial epilepsies in children: report of two cases. *Epilepsia* 1987; 28(4): 351-5.

Fejerman N, Tenenbaum S, Medina MT, Caraballo R, Soprano AM. Continuous spike-waves during slow-wave sleep and awake in a case of childhood epilepsy with occipital paroxysms: clinical correlations. *Epilepsia* 1991; 32(S1): 16.

Fejerman N, Caraballo R, Tenenbaum SN. Atypical evolutions of benign localization-related epilepsies in children: are they predictable? *Epilepsia* 2000; 41(4): 380-90.

Fejerman N, Caraballo R, Dalla Bernardina B. Atypical evolutions of benign focal epilepsies in childhood. In : Fejerman N, Caraballo R. *Benign focal epilepsies in infancy, childhood and adolescence*. Montrouge: John Libbey, 2007a: 179-200

Fejerman N, Caraballo R, Dalla Bernardina B. Benign childhood epilepsy with centrotemporal spikes. In : Fejerman N, Caraballo R. *Benign focal epilepsies in infancy, childhood and adolescence*. Montrouge: John Libbey 2007b: 77-113.

Fejerman N, Caraballo R, Cersosimo R, Ferraro SM, Galichio S, Amartino H. Sulthiame add-on therapy in children with focal epilepsies associated with encephalopathy related to electrical status epilepticus during slow sleep (ESES). *Epilepsia* 2012; 53(7): 1156-61.

Filippini M, Arzimanoglou A, Gobbi G. Neuropsychological approaches to epileptic encephalopathies. *Epilepsia* 2013; 54(S8): 38-44.

Gaggero R, Pistorio A, Pignatelli S, et al. Early classification of childhood focal idiopathic epilepsies: is it possible at the first seizure? *Eur J Paediatr Neurol* 2014; 18(3): 376-80.

Gastaut H. A new type of epilepsy: benign partial epilepsy of childhood with occipital spike-waves. *Clin Electroencephalogr* 1982; 13(1): 13-22.

Gibbs EL, Gillen HW, Gibbs FA. Disappearance and migration of epileptic foci in childhood. *Am J Dis Child* 1954; 88(5): 596-603.

Giordani B, Caveney AF, Laughrin D, et al. Cognition and behavior in children with benign epilepsy with centrotemporal spikes (BECTS). *Epilepsy Research* 2006; 70(1): 89-94.

Girirajan S, Rosenfeld JA, Cooper GM, et al. A recurrent 16p12.1 microdeletion supports a two-hit model for severe developmental delay. *Nat Genet* 2010; 42(3): 203-9.

Gobbi G, Boni A, Filippini M. The spectrum of idiopathic Rolandic epilepsy syndromes and idiopathic occipital epilepsies: from the benign to the disabling. *Epilepsia* 2006; 47(2): 62-6.

Goldberg-Stern H, Gonen OM, Sadeh M, Kivity S, Shuper A, Inbar D. Neuropsychological aspects of benign childhood epilepsy with centrotemporal spikes. *Seizure* 2010; 19(1): 12-6.

Goodman JH, Stewart M, Drislane FW. Autonomic disturbances. In: Engel J, Pedley TA. *Epilepsy. A comprehensive textbook*. Philadelphia: Lippincott, Williams & Wilkins, 2008: 1999-2005.

Gregory DL, Wong PK. Clinical relevance of a dipole field in Rolandic spikes. *Epilepsia* 1992; 33(1): 36-44.

Griffin C, Kleinjan DA, Doe B, van Heyningen V. New 3' elements control Pax6 expression in the developing pretectum, neural retina and olfactory region. *Mech Dev* 2002; 112(1-2): 89-100.

Grova C, Daunizeau J, Kobayashi E, et al. Concordance between distributed EEG source localization and simultaneous EEG-fMRI studies of epileptic spikes. *Neuroimage* 2008; 39(2): 755-64.

Guerrini R, Dravet C, Genton P, et al. Idiopathic photosensitive occipital lobe epilepsy. *Epilepsia* 1995; 36(9): 883-91.

Guerrini R, Bonanni P, Parmeggiani L, Belmonte A. Adolescent onset of idiopathic photosensitive occipital epilepsy after remission of benign Rolandic epilepsy. *Epilepsia* 1997; 38(7): 777-81.

Guerrini R, Genton P, Bureau M, et al. Multilobar polymicrogyria, intractable drop attack seizures, and sleep-related electrical status epilepticus. *Neurology* 1998; 51(2): 504-12.

Guerrini R, Bonanni P, Nardocci N, et al. Autosomal recessive Rolandic epilepsy with paroxysmal exercise-induced dystonia and writer's cramp: delineation of the syndrome and gene mapping to chromosome 16p12-11.2. *Ann Neurol* 1999; 45: 344-52.

Guerrini R, Parmeggiani A, Berta E. Occipital lobe seizures. In: Oxbury JM, Polkey CE, Duchowny MS. *Intractable focal epilepsy: medical and surgical treatment*. London: WB Saunders, 2000: 77-88.

Guzzetta F, Battaglia D, Veredice C, et al. Early thalamic injury associated with epilepsy and continuous spike-wave during slow sleep. *Epilepsia* 2005; 46(6): 889-900.

Han K, Holder Jr. JL, Schaaf CP, et al. SHANK3 overexpression causes manic-like behaviour with unique pharmacogenetic properties. *Nature* 2013; 503(7474): 72-7.

- Heinzen EL, Radtke RA, Urban TJ, *et al.* Rare deletions at 16p13.11 predispose to a diverse spectrum of sporadic epilepsy syndromes. *Am J Hum Genet* 2010;86(5):707-18.
- Helbig I, Mefford HC, Sharp AJ, *et al.* 15q13.3 microdeletions increase risk of idiopathic generalized epilepsy. *Nat Genet* 2009;41(2):160-2.
- Helbig I, Hartmann C, Mefford HC. Clarifying the role of the 22q11.2 microdeletion in juvenile myoclonic epilepsy. *Epilepsy Behav* 2013;29(3):589-90.
- Helbig I, Swinkels ME, Aten E, *et al.* Structural genomic variation in childhood epilepsies with complex phenotypes. *Eur J Hum Genet* 2014;22(7):896-901.
- Hernández-Vega Y, Smith A, Cockerill H, *et al.* The epidemiology of comorbidities in Rolandic epilepsy. *Epilepsia* 2014, Submitted.
- Hernández-Vega Y, Smith AB, Cockerill H, *et al.* Risk factors for reading disability in Rolandic Epilepsy. *Epilepsy & Behavior* 2015;53:174-9.
- Hirose S, Scheffer IE, Marini C, *et al.* SCN1A testing for epilepsy: application in clinical practice. *Epilepsia* 2013;54(5):946-52.
- Holtmann M, Becker K, Kentner-Figura B, Schmidt MH. Increased frequency of Rolandic spikes in ADHD children. *Epilepsia* 2003;44(9):1241-4.
- Holtmann M, Matei A, Hellmann U, Becker K, Poustka F, Schmidt MH. Rolandic spikes increase impulsivity in ADHD - a neuropsychological pilot study. *Brain Dev* 2006;28(10):633-40.
- Huiskamp G, van Der Meij W, van Huffelen A, van Nieuwenhuizen O. High resolution spatio-temporal EEG-MEG analysis of Rolandic spikes. *J Clin Neurophysiol* 2004;21(2):84-95.
- Ioannides AA, Dimitriadis SI, Saridis GA, *et al.* Source space analysis of event-related dynamic reorganization of brain networks. *Comput Math Methods Med* 2012:452503.
- Ishitobi MN, Nakasato K, Yamamoto K, Iinuma K. Opercular to interhemispheric source distribution of benign Rolandic spikes of childhood. *Neuroimage* 2005;25(2):417-23.
- Itsara AG, Cooper M, Baker C, *et al.* Population analysis of large copy number variants and hotspots of human genetic disease. *Am J Hum Genet* 2009;84(2):148-61.
- Kamada KM, Moller M, Saguer M, *et al.* Localization analysis of neuronal activities in benign Rolandic epilepsy using magnetoencephalography. *J Neurol Sci* 1998;154(2):164-72.
- Kanazawa O, Tohyama J, Akasaka N, Kamimura T. A magnetoencephalographic study of patients with Panayiotopoulos syndrome. *Epilepsia* 2005;46(7):1106-13.
- Kavros PM, Clarke T, Strug LJ, Halperin JM, Dorta NJ, Pal DK. Attention impairment in Rolandic epilepsy: systematic review. *Epilepsia* 2008a;49:1570-80.
- Kavros PM, Clarke T, Strug LJ, Halperin JM, Dorta NJ, Pal DK. Attentional Impairment in Rolandic epilepsy: systematic review. *Epilepsia* 2008b;49:1-11.
- Kevelam SH, Jansen FE, Binsbergen Ev FE, *et al.* Copy number variations in patients with electrical status epilepticus in sleep. *J Child Neurol* 2012;27(2):178-82.
- Kim KC, Lee DK, Go HS, *et al.* Pax6-dependent cortical glutamatergic neuronal differentiation regulates autism-like behavior in prenatally valproic Acid-exposed rat offspring. *Mol Neurobiol* 2014;49(1):512-28.
- Kobayashi K, Watanabe Y, Inoue T, Oka M, Yoshinaga H, Ohtsuka Y. Scalp-recorded high-frequency oscillations in childhood sleep-induced electrical status epilepticus. *Epilepsia* 2010;51(10):2190-4.
- Kobayashi K, Yoshinaga H, Toda Y, Inoue T, Oka M, Ohtsuka Y. High-frequency oscillations in idiopathic partial epilepsy of childhood. *Epilepsia* 2011;52(10):1812-9.
- Koutroumanidis M. Panayiotopoulos syndrome: an important electroclinical example of benign childhood system epilepsy. *Epilepsia* 2007;48(6):1044-53.
- Kramer U, Zelnik N, Lerman-Sagie T, Shahar E. Benign childhood epilepsy with centrotemporal spikes: clinical characteristics and identification of patients at risk for multiple seizures. *J Child Neurol* 2002;17:17-9.
- Kugler SL, Bali B, Lieberman P, *et al.* An autosomal dominant genetically heterogeneous variant of Rolandic epilepsy and speech disorder. *Epilepsia* 2008;49(6):1086-90.
- Lai CS, Fisher SE, Hurst JA, Vargha-Khadem F, Monaco AP. A forkhead-domain gene is mutated in a severe speech and language disorder. *Nature* 2001;413(6855):519-23.
- Lal D, Reinthaler EM, Altmüller J, *et al.* RBFOX1 and RBFOX3 mutations in Rolandic epilepsy. *PLoS One* 2013a;8(9):e73323.
- Lal D, Trucks H, Moller RS, *et al.* Rare exonic deletions of the RBFOX1 gene increase risk of idiopathic generalized epilepsy. *Epilepsia* 2013b;54(2):265-71.
- Lal D, Reinthaler EM, Schubert J, *et al.* DEPDC5 mutations in genetic focal epilepsies of childhood. *Ann Neurol* 2014;75(5):788-92.
- Landau WM, Kleffner FR. Syndrome of acquired aphasia with convulsive disorder in children. *Neurology* 1957;7:523-30.
- Leal A, Dias A, Vieira JP, Secca M, Jordao C. The BOLD effect of interictal spike activity in childhood occipital lobe epilepsy. *Epilepsia* 2006;47(9):1536-42.
- Lee HY, Huang Y, Bruneau N, *et al.* Mutations in the gene PRRT2 cause paroxysmal kinesigenic dyskinesia with infantile convulsions. *Cell Rep* 2012;1(1):2-12.
- Lee K, Kim Y, Lee SJ, *et al.* MDGAs interact selectively with neuroligin-2 but not other neuroligins to regulate inhibitory synapse development. *Proc Natl Acad Sci USA* 2013;110(1):336-41.
- Legarda S, Jayakar P, Duchowny M, Alvarez L, Resnick T. Benign Rolandic epilepsy: high central and low central subgroups. *Epilepsia* 1994;35(6):1125-9.
- Lemke JR, Beck-Wodl S, Zankl A, Riegel M, Kramer G, Dorn T. Juvenile myoclonic epilepsy with photosensitivity in a female with Velocardiofacial syndrome (del(22)(q11.2))-causal relationship or coincidence? *Seizure* 2009;18(9):660-3.

- Lemke JR, Hendrickx R, Geider K, et al. GRIN2B mutations in West syndrome and intellectual disability with focal epilepsy. *Ann Neurol* 2013a; 75(1): 147-54.
- Lemke JR, Lal D, Reinthaler EM, et al. Mutations in GRIN2A cause idiopathic focal epilepsy with Rolandic spikes. *Nat Genet* 2013b; 45(9): 1067-72.
- Lesca G, Rudolf G, Labalme A, et al. Epileptic encephalopathies of the Landau-Kleffner and continuous spike and waves during slow-wave sleep types: genomic dissection makes the link with autism. *Epilepsia* 2012; 53(9): 1526-38.
- Lesca G, Rudolf G, Bruneau N, et al. GRIN2A mutations in acquired epileptic aphasia and related childhood focal epilepsies and encephalopathies with speech and language dysfunction. *Nat Genet* 2013; 45(9): 1061-6.
- Lillywhite LM, Saling MM, Harvey AS, et al. Neuropsychological and functional MRI studies provide converging evidence of anterior language dysfunction in BECTS. *Epilepsia* 2009; 50(10): 2276-84.
- Lim ET, Raychaudhuri S, Sanders SJ, et al. Rare complete knockouts in humans: population distribution and significant role in autism spectrum disorders. *Neuron* 2013; 77(2): 235-42.
- Lin YY, Chang KP, Hsieh JC, et al. Magnetoencephalographic analysis of bilaterally synchronous discharges in benign Rolandic epilepsy of childhood. *Seizure* 2003a; 12(7): 448-55.
- Lin YY, Shih YH, Chang KP, et al. MEG localization of Rolandic spikes with respect to SI and SII cortices in benign Rolandic epilepsy. *Neuroimage* 2003b; 20(4): 2051-61.
- Lin YY, Hsiao FJ, Chang KP, Wu ZA, Ho LT. Bilateral oscillations for lateralized spikes in benign Rolandic epilepsy. *Epilepsy Res* 2006; 69(1): 45-52.
- Lindgren A, Kihlgren M, Melin L, Croona C, Lundberg S, Eeg-Olofsson O. Development of cognitive functions in children with Rolandic epilepsy. *Epilepsy & Behav* 2004; 5(6): 903-10.
- Loiseau P, Beaussart M. The seizures of benign childhood epilepsy with Rolandic paroxysmal discharges. *Epilepsia* 1973; 14: 381-9.
- Lundberg S, Frylmark A, Eeg-Olofsson O. Children with Rolandic epilepsy have abnormalities of oromotor and dichotic listening performance. *Dev Med Child Neurol* 2005; 47(9): 603-8.
- Lupski JR. Genomic disorders: structural features of the genome can lead to DNA rearrangements and human disease traits. *Trends Genet* 1998; 14(10): 417-22.
- Maquet P, Hirsch E, Metz-Lutz MN, et al. Regional cerebral glucose metabolism in children with deterioration of one or more cognitive functions and continuous spike-and-wave discharges during sleep. *Brain* 1995; 118(6): 1497-520.
- McBride DJ, Buckle A, Heyningen V, Kleinjan DA. DNase hypersensitivity and ultraconservation reveal novel, interdependent long-range enhancers at the complex Pax6 cis-regulatory region. *PLoS One* 2011; 6(12): e28616.
- Mefford HC, Eichler EE. Duplication hotspots, rare genomic disorders, and common disease. *Curr Opin Genet Dev* 2009; 19(3): 196-204.
- Mefford HC, Sharp AJ, Baker C, et al. Recurrent rearrangements of chromosome 1q21.1 and variable pediatric phenotypes. *N Engl J Med* 2008; 359(16): 1685-99.
- Mefford HC, Muhle H, Ostertag P, et al. Genome-wide copy number variation in epilepsy: novel susceptibility loci in idiopathic generalized and focal epilepsies. *PLoS Genet* 2010; 6(5): e1000962.
- Mefford HC, Yendle SC, Hsu C, et al. Rare copy number variants are an important cause of epileptic encephalopathies. *Ann Neurol* 2011; 70(6): 974-85.
- Metz-Lutz MN, Filippini M. Neuropsychological findings in Rolandic epilepsy and Landau-Kleffner syndrome. *Epilepsia* 2006; 47(2): 71-5.
- Metz-Lutz MN, Kleitz C, de Saint Martin A, Massa R, Hirsch E, Marescaux C. Cognitive development in benign focal epilepsies of childhood. *Dev Neurosci* 1999; 21(3-5): 182-90.
- Miller DT, Adam MP, Aradhya S, et al. Consensus statement: chromosomal microarray is a first-tier clinical diagnostic test for individuals with developmental disabilities or congenital anomalies. *Am J Hum Genet* 2010; 86(5): 749-64.
- Minami T, Gondo K, Yamamoto T, Yanai S, Tasaki K, Ueda K. Magnetoencephalographic analysis of Rolandic discharges in benign childhood epilepsy. *Ann Neurol* 1996; 39(3): 326-34.
- Moller RS, Weber YGLKlitten, Weber, et al. Exon-disrupting deletions of NRXN1 in idiopathic generalized epilepsy. *Epilepsia* 2013; 54(2): 256-64.
- Monjauze C, Tuller L, Hommet C, Barthez MA, Khomsi A. Language in benign childhood epilepsy with centro-temporal spikes abbreviated form: Rolandic epilepsy and language. *Brain & Language* 2005; 92(3): 300-8.
- Montenegro MA, Guerreiro MM. Electrical status epilepticus of sleep in association with topiramate. *Epilepsia* 2002; 43(11): 1436-40.
- Morikawa T. Rolandic discharges in benign childhood epilepsy with centrotemporal spikes, and in other forms of partial epilepsies. *Epileptic Disord* 2000; 2(1): S23-8.
- Neubauer BA, Fiedler B, Himmelein B, et al. Centrotemporal spikes in families with Rolandic epilepsy: linkage to chromosome 15q14. *Neurology* 1998; 51(6): 1608-12.
- Nguyen L, Humbert S, Saudou F, Chariot A. Elongator - an emerging role in neurological disorders. *Trends Mol Med* 2009; 16(1): 1-6.
- Nicolai J, Aldenkamp AP, Arends J, Weber JW, Vles JSH. Cognitive and behavioral effects of nocturnal epileptiform discharges in children with benign childhood epilepsy with centrotemporal spikes. *Epilepsy & Behav* 2006; 8: 56-70.
- Niedermeyer E, McKusick VA, Brunt P, Mahloudji M. The EEG in familial dysautonomia (Riley-Day syndrome). *Electroencephalogr Clin Neurophysiol* 1967; 22(5): 473-5.
- Nieuwenhuis L, Nicolai J. The pathophysiological mechanisms of cognitive and behavioral disturbances in children with Landau-Kleffner syndrome or epilepsy with continuous spike-and-waves during slow-wave sleep. *Seizure* 2006; 15(4): 249-58.

- Northcott E, Connolly AM, Berroya A, *et al.* Memory and phonological awareness in children with Benign Rolandic Epilepsy compared to a matched control group. *Epilepsy Res* 2007; 75(1): 57-62.
- Ohtsu M, Oguni H, Hayashi K, Funatsuka M, Imai K, Osawa M. EEG in children with early-onset benign occipital seizure susceptibility syndrome: Panayiotopoulos syndrome. *Epilepsia* 2003; 44(3): 435-42.
- Oser N, Hubacher M, Specht K, Datta AN, Weber P, Penner IK. Default mode network alterations during language task performance in children with benign epilepsy with centrotemporal spikes (BECTS). *Epilepsy Behav* 2014; 33: 12-7.
- Otero G, Fellows J, Li Y, *et al.* Elongator, a multisubunit component of a novel RNA polymerase II holoenzyme for transcriptional elongation. *Mol Cell* 1999; 3(1): 109-18.
- Overvliet GM, Besseling RM, Vles JS, *et al.* Nocturnal epileptiform EEG discharges, nocturnal epileptic seizures, and language impairments in children: review of the literature. *Epilepsy Behav* 2010; 19(4): 550-8.
- Paetau R. Magnetoencephalography in Landau-Kleffner syndrome. *Epilepsia* 2009; 50 Suppl 7: 51-4.
- Paetau R, Granstrom ML, Blomstedt G, Jousmaki V, Korkman M, Liukkonen E. Magnetoencephalography in presurgical evaluation of children with the Landau-Kleffner syndrome. *Epilepsia* 1999; 40(3): 326-35.
- Pal DK, Li W, Clarke T, Lieberman P, Strug LJ. Pleiotropic effects of the 11p13 locus on developmental verbal dyspraxia and EEG centrotemporal sharp waves. *Genes Brain Behav* 2010; 9(8): 1004-12.
- Panayiotopoulos CP. Benign nocturnal childhood occipital epilepsy: a new syndrome with nocturnal seizures, tonic deviation of the eyes, and vomiting. *J Child Neurol* 1989; 4(1): 43-9.
- Panayiotopoulos CP. Occipital seizures and epilepsies in children. In : Anderman F, Beaumanoir A, Mira L, Tassinari CA. *Benign childhood epilepsy with occipital paroxysms*. London: John Libbey, 1993: 151-64.
- Panayiotopoulos CP. The birth and evolution of the concept of Panayiotopoulos syndrome. *Epilepsia* 2007; 48(6): 1041-3.
- Panayiotopoulos CP, Michael M, Sanders S, Valeta T, Koutroumanidis M. Benign childhood focal epilepsies: assessment of established and newly recognized syndromes. *Brain* 2008; 131(9): 2264-86.
- Papavasiliou A, Mattheou D, Bazigou H, Kotsalis C, Paraskevoulakos E. Written language skills in children with benign childhood epilepsy with centrotemporal spikes. *Epilepsy & Behav* 2005; 6(1): 50-8.
- Pataaraia E, Feucht M, Lindinger G, Aull-Watschinger S, Baumgartner C. Combined electroencephalography and magnetoencephalography of interictal spikes in benign Rolandic epilepsy of childhood. *Clin Neurophysiol* 2008; 119(3): 635-41.
- Patry G, Lyagoubi S, Tassinari CA. Subclinical electrical status epilepticus induced by sleep in children: a clinical and EEG study of six cases. *Arch Neurol* 1971; 24: 242-52.
- Picard A, Cheliout Heraut F, Bouskraoui M, Lemoine M, Lacert P, Delattre J. Sleep EEG and developmental dysphasia. *Dev Med Child Neurol* 1998; 40(9): 595-9.
- Piccinelli P, Borgatti R, Aldini A, *et al.* Academic performance in children with Rolandic epilepsy. *Dev Med Child Neurol* 2008; 50(5): 353-6.
- Pinton F, Ducot B, Motte J, *et al.* Cognitive functions in children with benign childhood epilepsy with centrotemporal spikes (BECTS). *Epileptic Disord* 2006; 8(1): 11-23.
- Piton A, Redin C, Mandel JL. XLID-causing mutations and associated genes challenged in light of data from large-scale human exome sequencing. *Am J Hum Genet* 2013; 93(2): 368-83.
- Porciatti V, Bonanni P, Fiorentini A, Guerrini R. Lack of cortical contrast gain control in human photosensitive epilepsy. *Nat Neurosci* 2000; 3(3): 259-63.
- Prats JM, Garaizar C, Garcia-Neto ML, Madoz P. Antiepileptic drugs and atypical evolution of idiopathic partial epilepsy. *Pediatric Neurology* 1998; 18: 402-6.
- Reutlinger C, IHelbig I, Gawelczyk B, *et al.* Deletions in 16p13 including GRIN2A in patients with intellectual disability, various dysmorphic features, and seizure disorders of the Rolandic region. *Epilepsia* 2010; 51(9): 1870-3.
- Richardson MP. Large scale brain models of epilepsy: dynamics meets connectomics. *J Neurol Neurosurg Psychiatry* 2012; 83(12): 1238-48.
- Riva D, Vago C, Franceschetti S, *et al.* Intellectual and language findings and their relationship to EEG characteristics in benign childhood epilepsy with centrotemporal spikes. *Epilepsy & Behav* 2007; 10(2): 278-85.
- Robinson SE, Nagarajan SS, Mantle M, Gibbons V, Kirsch H. Localization of interictal spikes using SAM(g2) and dipole fit. *Neurol Clin Neurophysiol* 2004; 2004: 74.
- Roll P, Rudolf G, Pereira S, *et al.* SRPX2 mutations in disorders of language cortex and cognition. *Hum Mol Genet* 2006; 15(7): 1195-207.
- Roll P, Vernes SC, Bruneau N, *et al.* Molecular networks implicated in speech-related disorders: FOXP2 regulates the SRPX2/uPAR complex. *Hum Mol Genet* 2010; 19(24): 4848-60.
- Roulet-Perez E, Deonna T, Despland PA. Prolonged intermittent drooling and oromotor dyspraxia in benign childhood epilepsy with centrotemporal spikes. *Epilepsia* 1989; 30(5): 564-8.
- Rubia K, Smith A, Taylor E. Performance of children with ADHD on a test battery of impulsiveness. *Child Neuropsychology* 2007; 13(3): 276-304.
- Rudolf G, Valenti MP, Hirsch E, Szepetowski P. From Rolandic epilepsy to continuous spike-and-waves during sleep and Landau-Kleffner syndromes: insights into possible genetic factors. *Epilepsia* 2009; 50(7): 25-8.
- Ryan SG. Partial epilepsy: chinks in the armour. *Nat Genet* 1995; 10(1): 4-6.
- Salmi M, Bruneau N, Cillario J, *et al.* Tubacin prevents neuronal migration defects and epileptic activity caused by rat *SrpX2* silencing in utero. *Brain* 2013; 136(8): 2457-73.

- Saltik S, Uluduz D, Cokar O, Demirbilek V, Dervent A. A clinical and EEG study on idiopathic partial epilepsies with evolution into ESES spectrum disorders. *Epilepsia* 2005; 46(4): 524-33.
- Scheffer IE, Jones L, Pozzebon M, Howell RA, Saling MM, Berkovic SF. Autosomal dominant Rolandic epilepsy and speech dyspraxia: a new syndrome with anticipation. *Ann Neurol* 1995; 38(4): 633-42.
- Shalev L, Tsal Y, Mevorach C. Computerized Progressive Attentional Training (CPAT) Program: effective direct intervention for children with ADHD. *Child Neuropsychology* 2007; 13(4): 382-8.
- Sharp AJ. Emerging themes and new challenges in defining the role of structural variation in human disease. *Hum Mutat* 2009; 30(2): 135-44.
- Shaw CJ, Lupski JR. Implications of human genome architecture for rearrangement-based disorders: the genomic basis of disease. *Hum Mol Genet* 2004; 13(1): R57-64.
- Shields WD, Saslow E. Myoclonic, atonic, and absence seizures following institution of carbamazepine therapy in children. *Neurology* 1983; 33(11): 1487-9.
- Simpson CL, Lemmens R, Miskiewicz K, et al. Variants of the elongator protein 3 (ELP3) gene are associated with motor neuron degeneration. *Hum Mol Genet* 2009; 18(3): 472-81.
- Siniatchkin M, Capovilla G. Functional neuroimaging in epileptic encephalopathies. *Epilepsia* 2013; 54(8): 27-33.
- Siniatchkin M, Groening K, Moehring J, et al. Neuronal networks in children with continuous spikes and waves during slow sleep. *Brain* 2010; 133(9): 2798-813.
- Slaugenhaupt SA, Blumenfeld A, Gill SP, et al. Tissue-specific expression of a splicing mutation in the IKBKAP gene causes familial dysautonomia. *Am J Hum Genet* 2001; 68(3): 598-605.
- Smith A, Taylor E, Brammer M, Toone B, Rubia K. Task specific hypoactivation in prefrontal and temporoparietal brain regions during motor inhibition and task switching in medication-naïve children and adolescents with ADHD. *Am J Psychiatry* 2006; 163: 1044-51.
- Smith AB, Taylor E, Brammer M, Halari R, Rubia K. Reduced activation in right lateral prefrontal cortex and anterior cingulate cortex in medication-naïve adolescents with Attention Deficit Hyperactivity Disorder during time discrimination. *J Child Psychol Psychiatry* 2008; 49(9): 977-85.
- Smith A, Kavros PM, Clarke T, Dorta N, Tremont G, Pal DK. A neurocognitive endophenotype associated with Rolandic Epilepsy. *Epilepsia* 2012; 53(4): 705-11.
- Smith AB, Bajojo O, Pal DK. A meta-analysis of literacy and language in children with Rolandic Epilepsy. *Dev Med Child Neurol* 2015; 57(11): 1019-26.
- Snowling MJ. Phonological processing and developmental dyslexia. *J Res Read* 1995; 18(2): 132-8.
- Sobel DF, Aung M, Otsubo H, Smith MC. Magnetoencephalography in children with Landau-Kleffner syndrome and acquired epileptic aphasia. *AJNR Am J Neuroradiol* 2000; 21(2): 301-7.
- Specchio N, Trivisano M, Di Ciommo V, et al. Panayiotopoulos syndrome: a clinical, EEG, and neuropsychological study of 93 consecutive patients. *Epilepsia* 2010; 51(10): 2098-107.
- Spira EG, Fischel JE. The impact of preschool inattention, hyperactivity, and impulsivity on social and academic development: a review. *J Child Psychol Psychiatry* 2005; 46(7): 755-73.
- Staden U, Isaacs E, Boyd SG, Brandl U, Neville BG. Language dysfunction in children with Rolandic epilepsy. *Neuropediatrics* 1998; 29(5): 242-8.
- Staden U, Isaacs E, Boyd S, Brandl U, Neville B. Language dysfunction in children with Rolandic epilepsy. *Neuropediatrics* 2007; 29(05): 242-8.
- Steinlein OK, Mulley JC, Propping P, et al. A missense mutation in the neuronal nicotinic receptor alpha 4 subunit is associated with autosomal dominant nocturnal frontal lobe epilepsy. *Nature Genetics* 1995; 11: 201-3.
- Striano P, Capovilla G. Epileptic encephalopathy with continuous spikes and waves during sleep. *Curr Neurol Neurosci Rep* 2013; 13(7): 360.
- Strug LJ, Clarke T, Chiang T, et al. Centrottemporal sharp wave EEG trait in Rolandic epilepsy maps to Elongator Protein Complex 4 (ELP4). *Eur J Hum Genet* 2009; 17: 1171-81.
- Strug LJ, Addis L, Chiang T, et al. The genetics of reading disability in an often excluded sample: novel loci suggested for reading disability in Rolandic epilepsy. *PLoS One* 2012; 7(7): e40696.
- Svejstrup JQ. Elongator complex: how many roles does it play? *Curr Opin Cell Biol* 2007; 19(3): 331-6.
- Tassinari CA, Rubboli G, Volpi L, et al. Encephalopathy with electrical status epilepticus during slow sleep or ESES syndrome including the acquired aphasia. *Clin Neurophysiol* 2000; 111(2): S94-102.
- Tassinari CA, Rubboli G, Volpi L. Electrical status epilepticus during slow sleep (ESES or CSWS) including acquired epileptic aphasia (Landau-Kleffner syndrome). In: Roger J, Bureau M, Dravet C. *Epileptic syndromes in infancy, childhood and adolescence*. Montrouge: John Libbey Eurotext Ltd, 2005: 295-314.
- Taylor JG, Ioannides AA, Muller-Gartner HW. Mathematical analysis of lead field expansions. *IEEE Trans Med Imaging* 1999; 18(2): 151-63.
- Tedrus GM, Fonseca LC, Melo E, Ximenes VL. Educational problems related to quantitative EEG changes in benign childhood epilepsy with centrottemporal spikes. *Epilepsy & Behav* 2009; 15(4): 486-90.
- Urbain C, Di Vincenzo T, Peigneux P, Van Bogaert P. Is sleep-related consolidation impaired in focal idiopathic epilepsies of childhood? A pilot study. *Epilepsy Behav* 2011; 22(2): 380-4.
- Valeta T. Parental attitude, reaction and education in benign childhood focal seizures. In: *The epilepsies: seizures, syndromes and management*. Panayiotopoulos CP. Oxford: Bladon Medical Publishing, 2005: 258-61.

- Valeta T. Psychosocial impact of epilepsy in children and family. In: Panayiotopoulos CP. *Atlas of epilepsies*. London: Springer, 2010: 1371-3.
- Valeta T. Parental reactions and needs in benign childhood focal seizures. *Epilepsia* 2011; 52(S6): 122-3.
- Valeta T. Parental reactions in benign childhood focal seizures. *Epilepsia* 2012; 53(S5): 222-3.
- Valeta T, Sogawa Y, Moshe SL. Impact of focal seizures on patients and family. In: Panayiotopoulos CP, Benbadis S, Sisodiya S. *Focal epilepsies: seizures, syndromes and management*. Oxford: Medicinæ, 2008: 5.
- Van Bogaert P. Epileptic encephalopathy with continuous spike-waves during slow-wave sleep including Landau-Kleffner syndrome. *Handbook Clin Neurol* 2013; 111: 635-40.
- van der Meij W, Van Huffelen AC, Wieneke GH, Willemse J. Sequential EEG mapping may differentiate epileptic from non-epileptic Rolandic spikes. *Electroencephalogr Clin Neurophysiol* 1992; 82(6): 408-14.
- van der Meij W, Wieneke GH, van Huffelen AC. Dipole source analysis of Rolandic spikes in benign Rolandic epilepsy and other clinical syndromes. *Brain Topogr* 1993; 5(3): 203-13.
- van der Meij W, Huiskamp GJ, Rutten GJ, Wieneke GH, van Huffelen AC, van Nieuwenhuizen O. The existence of two sources in Rolandic epilepsy: confirmation with high resolution EEG, MEG and fMRI. *Brain Topogr* 2001; 13(4): 275-82.
- Vears DF, Tsai MH, Sadleir G, et al. Clinical genetic studies in benign childhood epilepsy with centrotemporal spikes. *Epilepsia* 2012; 53(2): 319-24.
- Veggiotti P, Beccaria F, Guerrini R, Capovilla G, Lanzi G. Continuous spike-and-wave activity during slow-wave sleep: syndrome or EEG pattern? *Epilepsia* 1999; 40(11): 1593-601.
- Veggiotti P, Pera MC, Teutonico F, Brazzo D, Balottin U, Tasinari CA. Therapy of encephalopathy with status epilepticus during sleep (ESES/CSWS syndrome): an update. *Epileptic Disord* 2012; 14(1): 1-11.
- Verrotti A, Latini G, Trotta D, et al. Typical and atypical Rolandic epilepsy in childhood: a follow-up study. *Pediatr Neurol* 2002; 26(1): 26-9.
- Verrotti A, D'Egidio C, Agostinelli S, Parisi P, Chiarelli F, Coppola G. Cognitive and linguistic abnormalities in benign childhood epilepsy with centrotemporal spikes. *Acta Paediatrica* 2010; 100(5): 768-72.
- Verrotti A, Filippini M, Matricardi S, Agostinelli MF, Gobbi G. Memory impairment and benign epilepsy with centrotemporal spike (BECTS): a growing suspicion. *Brain Cogn* 2014; 84(1): 123-31.
- Volkl-Kernstock S, Bauch-Prater S, Ponocny-Seliger E, Feucht M. Speech and school performance in children with benign partial epilepsy with centro-temporal spikes (BCECTS). *Seizure* 2009; 18(5): 320-6.
- Vrba J, Robinson SE. Signal processing in magnetoencephalography. *Methods* 2001; 25(2): 249-71.
- Weglage J, Demsky A, Pietsch M, Kurlemann G. Neuropsychological, intellectual, and behavioral findings in patients with centrottemporal spikes with and without seizures. *Developmental Medicine and Child Neurology* 1997; 39(10): 646-51.
- Wolf P. Basic principles of the ILAE syndrome classification. *Epilepsy Res* 2006; 70(1): S20-6.
- Wolff M, Weiskopf N, Serra E, Preissl H, Birbaumer N, Kraegeloh-Mann N. Benign partial epilepsy in childhood: selective cognitive deficits are related to the location of focal spikes determined by combined EEG/MEG. *Epilepsia* 2005; 46(10): 1661-7.
- Wong PK. Stability of source estimates in Rolandic spikes. *Brain Topogr* 1989; 2(1-2): 31-6.
- Yoshinaga H, Amano R, Oka E, Ohtahara S. Dipole tracing in childhood epilepsy with special reference to Rolandic epilepsy. *Brain Topogr* 1992; 4(3): 193-9.
- Yoshinaga H, Koutroumanidis M, Shirasawa A, Kikumoto K, Ohtsuka Y, Oka E. Dipole analysis in panayiotopoulos syndrome. *Brain Dev* 2005; 27(1): 46-52.
- Yoshinaga H, Koutroumanidis M, Kobayashi K, et al. EEG dipole characteristics in Panayiotopoulos syndrome. *Epilepsia* 2006; 47(4): 781-7.
- Yoshinaga H, Kobayashi K, Akiyama T, Shibata T, Endoh F, Ohtsuka Y. Clinical implications of preceding positive spikes in patients with benign partial epilepsy and febrile seizures. *Brain Dev* 2013; 35(4): 299-306.
- Yoshinaga H, Kobayashi K, Shibata T, Inoue T, Oka M, Akiyama T. Manifestation of both emetic seizures and sylvian seizures in the same patients with benign partial epilepsy. *Brain Dev* 2015; 37(1): 13-7.
- You SJ, Kim DS, Ko TS. Benign childhood epilepsy with centro-temporal spikes (BCECTS): early onset of seizures is associated with poorer response to initial treatment. *Epileptic Disord* 2006; 8(4): 285-8.
- Zhang F, Carvalho CM, Lupski JR. Complex human chromosomal and genomic rearrangements. *Trends Genet* 2009; 25(7): 298-307.

TEST YOURSELF



- (1) What are the epilepsies in the idiopathic focal epilepsy group and what is the evidence that they are related or form part of a spectrum or continuum? What other clinical overlaps exist?
- (2) Name two advanced electrophysiological techniques and discuss their contribution to understanding idiopathic focal epilepsies.
- (3) What neurodevelopmental complications and comorbidities occur in Rolandic epilepsy?

Note: Reading the manuscript provides an answer to all questions. Correct answers may be accessed on the website, www.epilepticdisorders.com, under the section "The EpiCentre".